Minimally Invasive Endoscopic Skull Base Surgery for Pituitary Tumors

Hermes G. Garcia, MD

Orlando Health Neurosurgery

Orlando Health Neuroscience and Rehabilitation Institute

Orlando Health Cancer Center

ORLANDO HEALTH®

Orlando Regional Medical Center

Pituitary Lesions

- ***Pituitary adenomas***
  - Non-Secretary / Non-Functional
  - Secretary / Functional
    - PRL-Secreting / Prolactinoma
    - ACTH-Secreting / Cushing's Disease
    - GH-Secreting / Acromegaly
  - Apoplexy
- ***Rathke's cleft cysts***
- **Craniopharyngiomas**
- Meningiomas
- Rarities: pituicytoma, hypophysitis, clival plasmacytoma, germ cell tumors
- *Work-force of endoscopic skull base surgery*

Pituitary Adenomas

- 10-15% of all primary intracranial neoplasms (third most common primary intracranial tumor)
- 3rd – 6th decade of life
- “Benign”.
- Presentation:
  - Incidental
  - Mass effect:
    - Optic chiasm -> bitemporal vision loss
    - Pituitary -> pituitary insufficiency.
  - Hypersecretory states

2017 WHO Pituitary Classification

- Classification of pituitary tumors according to cell lineage/transcription factors.

Pituitary adenomas	Somatotroph adenoma
	Lactotroph adenoma
	Thyrotroph adenoma
	Corticotroph adenoma
	Gonadotroph adenoma
	Null-cell adenoma
	Plurihormonal and double adenomas
Pituitary carcinoma	
Pituitary blastoma	
Tumors of the posterior pituitary	Pituicytoma
	Granular cell tumor of the sella
	Spindle cell oncocytoma
	Sellar ependymoma
Neuronal and paraneuronal tumors	Gangliocytoma and mixed gangliocytoma-adenoma
	Neurocytoma
	Paraganglioma
	Neuroblastoma
Craniopharyngioma	Adamantinomatous craniopharyngioma
	Papillary craniopharyngioma
Mesenchymal and stromal tumors	Meningioma
	Schwannoma
	Chordoma, NOS
	Chondroid chordoma
	“Dedifferentiated” chordoma
	Solitary fibrous tumor/hemangiopericytoma
	Grade 1 SFT/HPC
	Grade 2 SFT/HPC
	Grade 3 SFT/HPC
Hematolymphoid tumors	
Germ cell tumors	Germinoma
	Yolk sac tumor
	Embryonal carcinoma
	Choriocarcinoma
	Teratoma, NOS
	Mature teratoma
	Immature teratoma
	Teratoma with malignant transformation
	Mixed germ cell tumor
Secondary tumors	

Table 2 Adenohypophyseal cell lineage basis for the 2017 classification of pituitary adenomas

Lineage	Main transcription factors and other co-factors	Adenohypophyseal cell
Acidophilic lineage	PIT-1	Somatotrophs
	PIT-1, ERα	Lactotrophs
	PIT-1, GATA-2	Thyrotrophs
Corticotroph lineage	T-PIT	Corticotrophs
Gonadotroph lineage	SF-1; GATA-2, ERα	Gonadotrophs

PIT-1 pituitary-specific POU-class homeodomain transcription factor 1, *ERα* estrogen receptor α, *GATA-2* member of the GATA family of zinc-finger transcriptional regulatory proteins, *T-PIT* T-box family member TBX19, *SF-1* steroidogenic factor 1 [48; for review]

Pituitary Adenoma Work-Up

- Imaging: T1 post contrast coronal and sagittal planes
- Vision exam; visual fields test (Humphrey)
- Endocrine work-up
  - Diagnose a hyper-secretary pituitary tumor
  - Establish baseline
  - TSH, fT4, PRL, ACTH, 7am cortisol, FSH/LH, free/ total testosterone, estrogen, GH, IGF-1
  - BMP to check Na
- Advanced endocrinological tests
  - Cushing's disease work-up

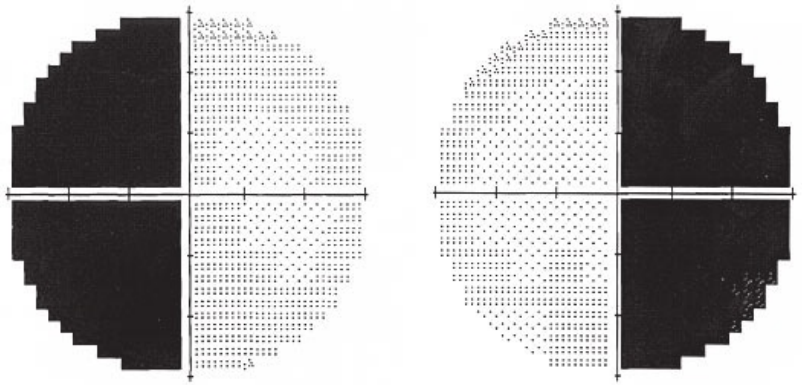

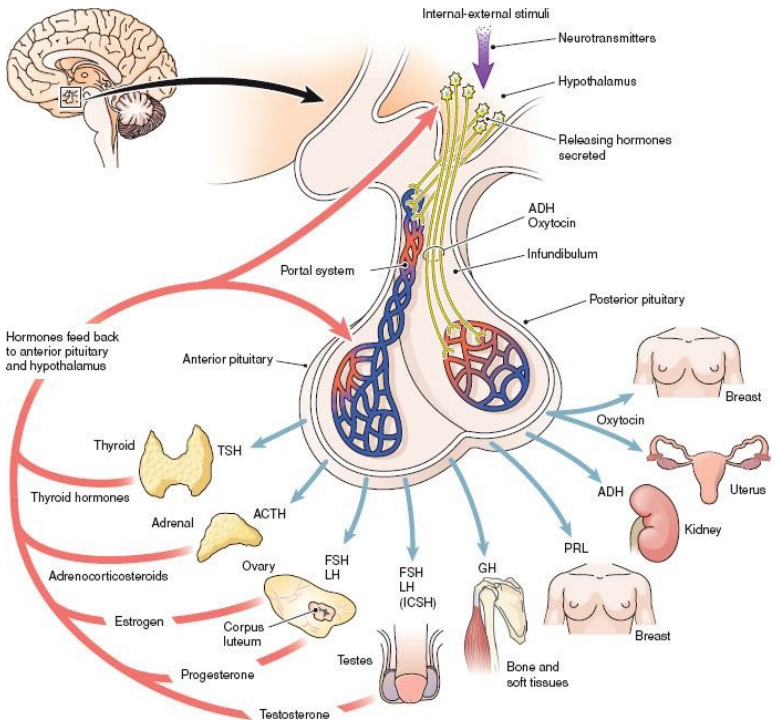

Visual Field Defects

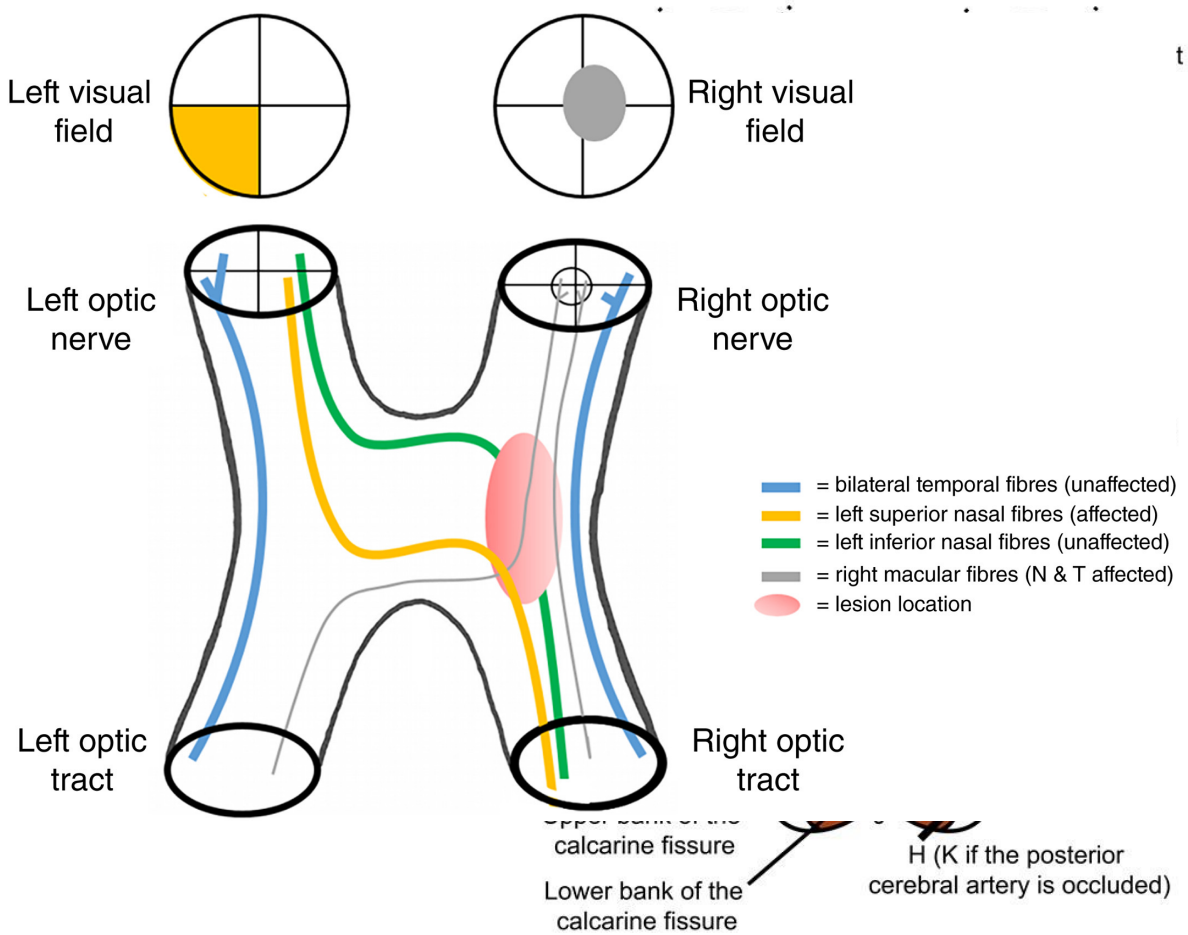

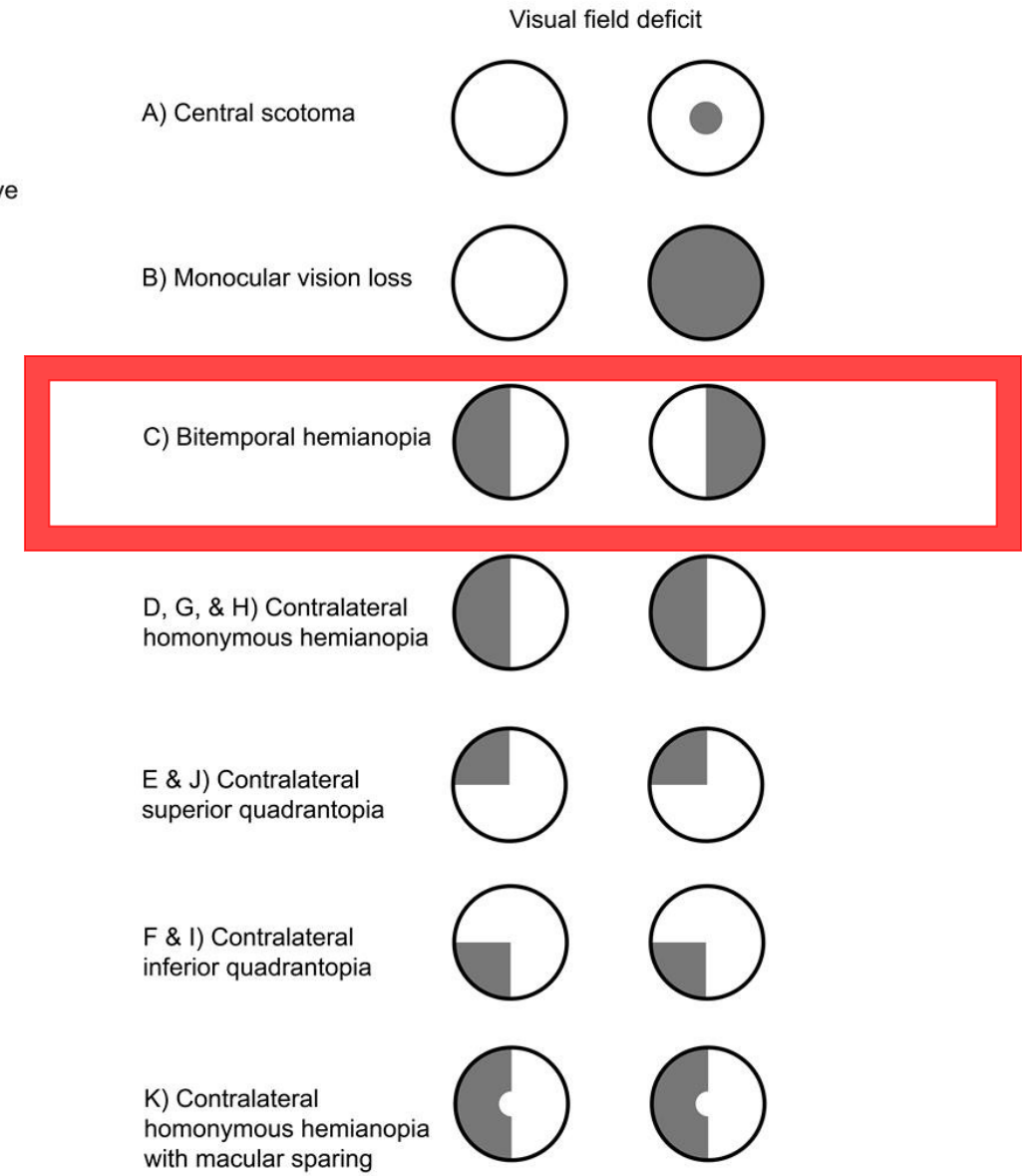

Left CN VI Palsy

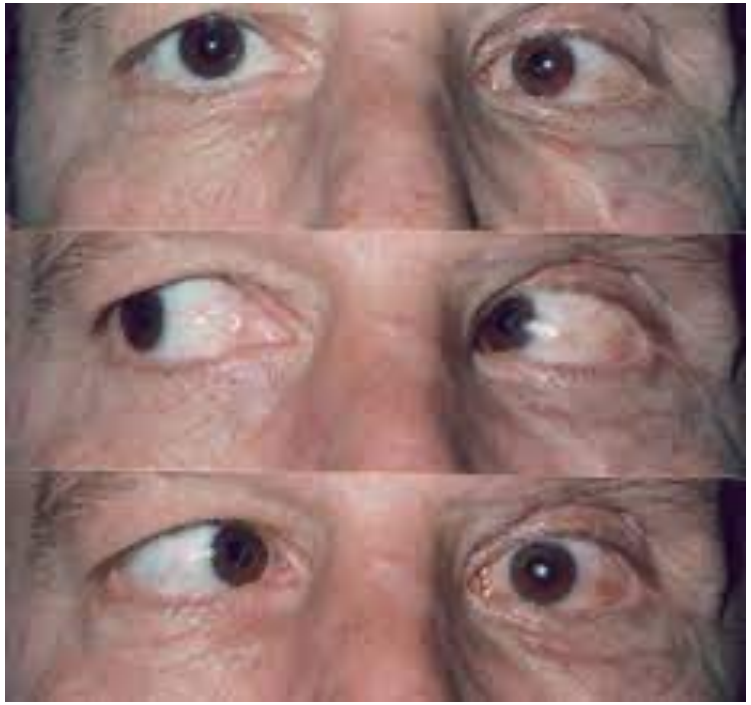

Left CN III Palsy

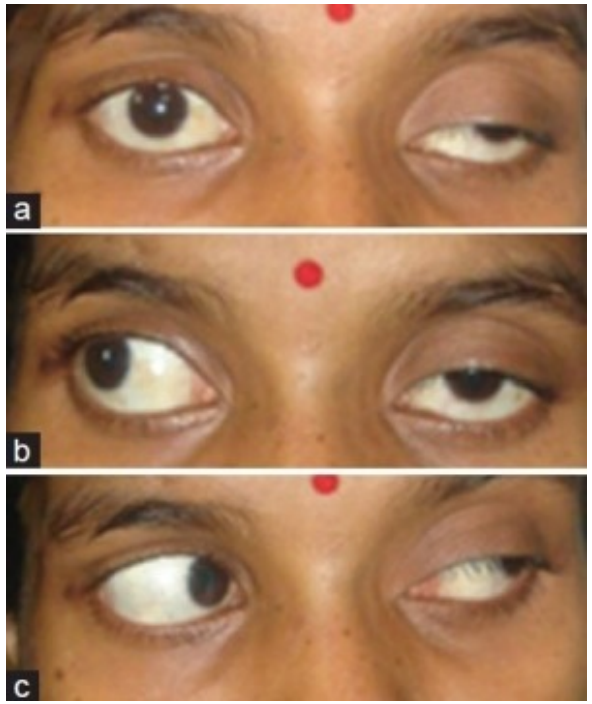

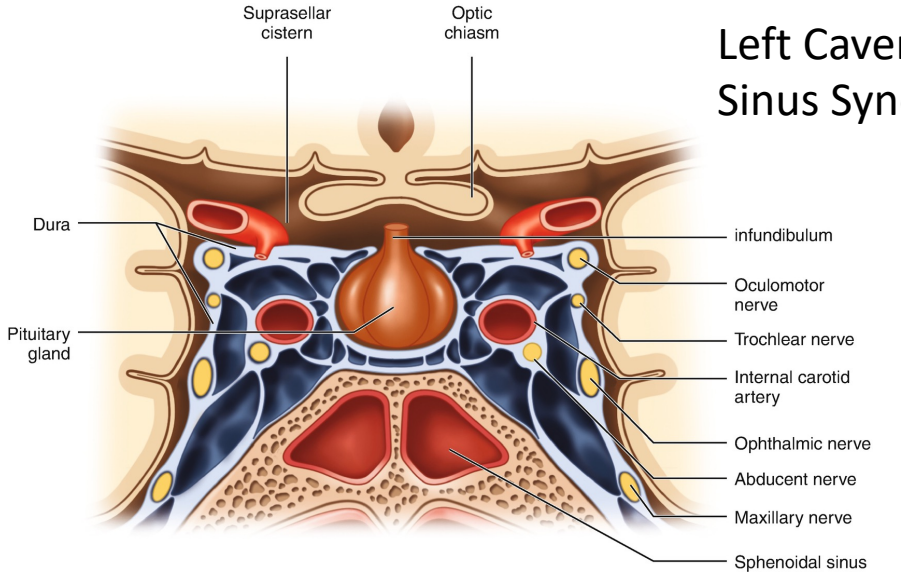

Left Cavernous Sinus Syndrome

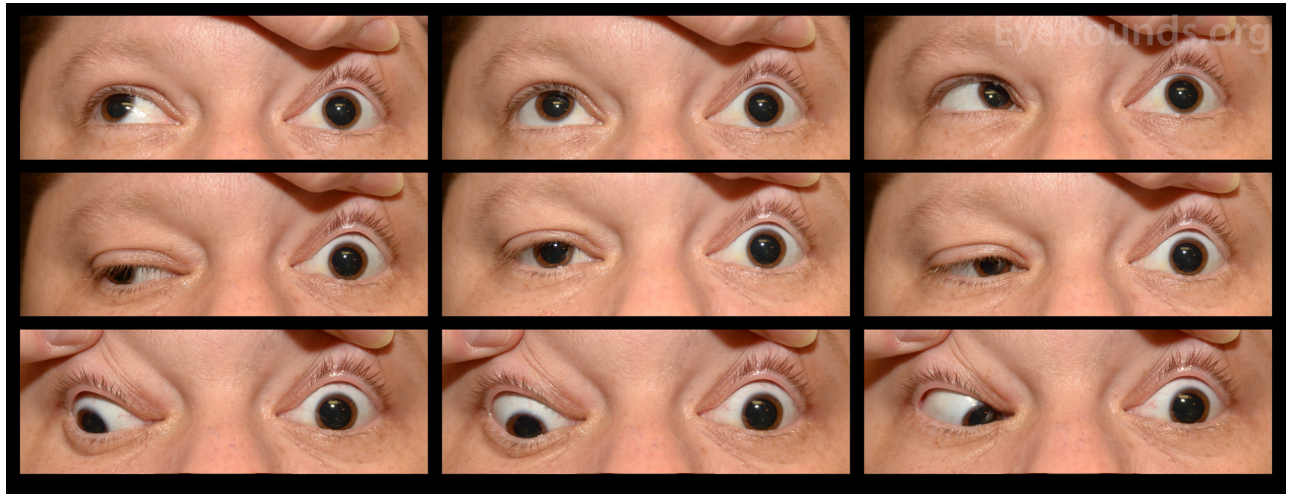

Normal Pitutiary MRI

T1 post-contrast sagittal

T1 post-contrast coronal

Microadenoma
(<1cm)

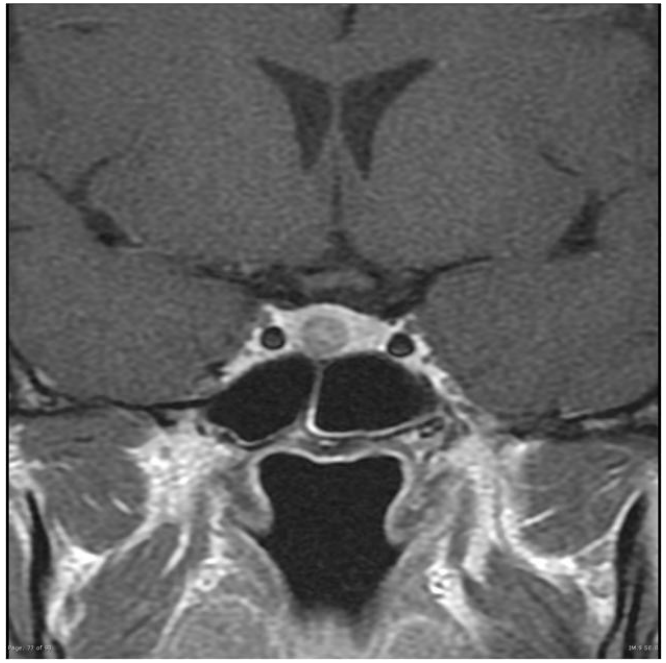

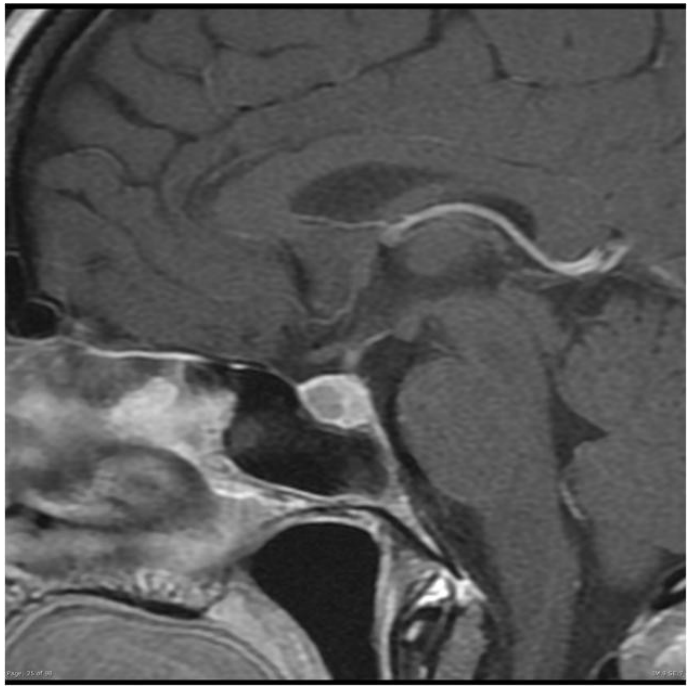

Macroadenoma
(>1cm)

Functional Pituitary Adenomas

- Most commonly PRL (**Prolactinoma**)-> hyperprolactinemia
  - Females: amenorrhea, lactation
  - Males: erectile dysfunction
  - *PRL > 200 (< 200 = Stalk effect)*
  - Dilutions in clinically suspected but “low PRL” (Hook effect)
  - <u>Treatment</u>: Dopamine agonist (Cabergoline, bromocriptine)
- ACTH oversecretion: **Cushing’s disease**
  - <u>Treatment</u>: surgery
  - Other: radiation, medical.
- GH oversecretion: **Acromegaly**
  - “Surgical” disease
  - Medical management: octreotide, pegvisomant

PRL > 2000


SAG T1 FS POST
MR48525-19
Series #:13
8/28/2019
18:54:36
Image #:8/15
3.00 mm
0.30
S
A
Regular
3
TRTR 452


AX T1 FS POST
MR48525-19
Series #:16
8/28/2019
19:02:45
Image #:8/24
5.00 mm
1.25
A
R
OrReg Espree
RUDAS, ISRAEL, E
0004918465
12/4/1984
M
HEAD^ROUTINES
8/28/2019
SIEMENS
Espree
Zoom:97.9%
Key Image
Regular
1
TRTR 652
TETE 17
ww/wl 1029/498

Signs and symptoms of Cushing syndrome

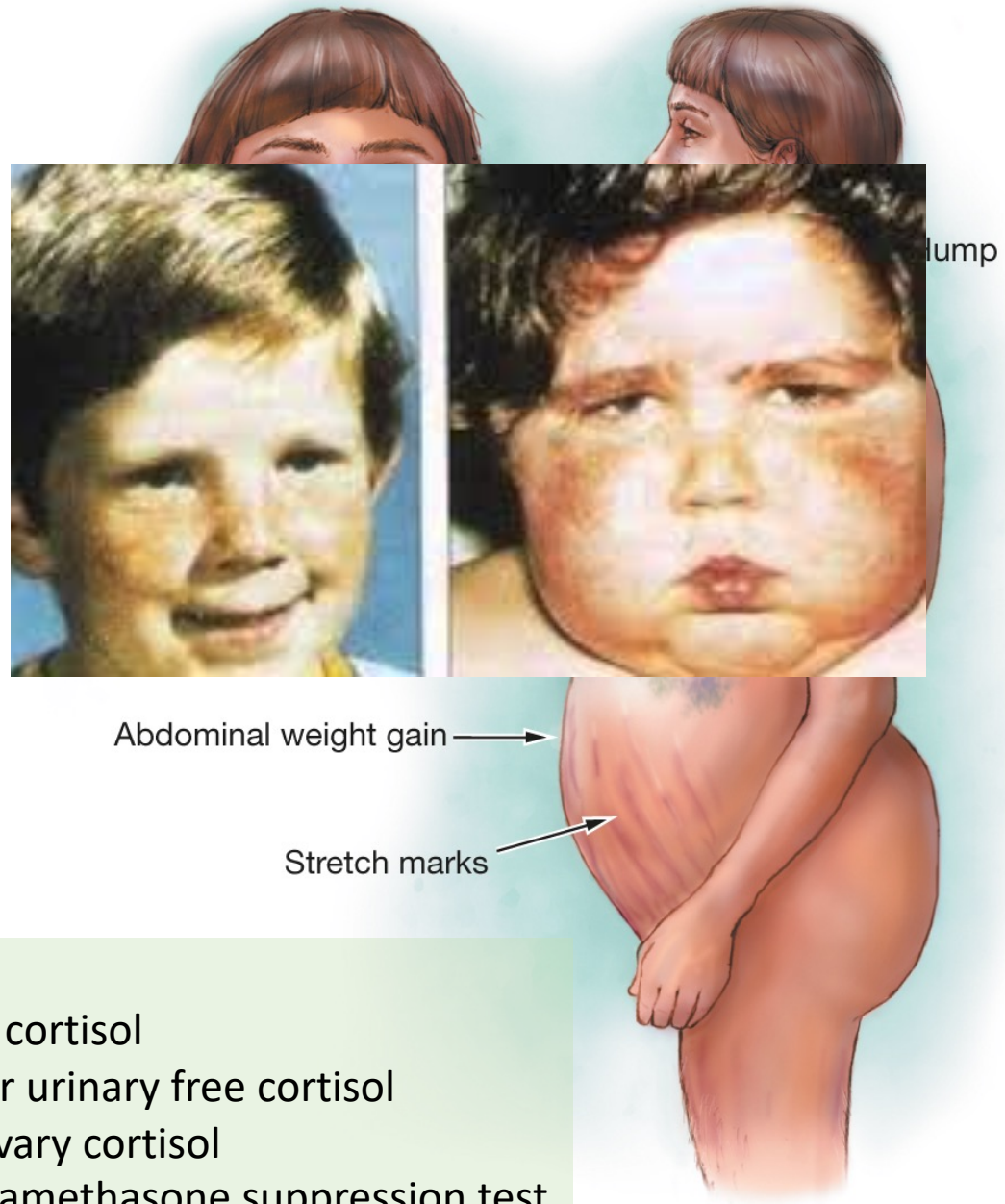

Dx:
-AM cortisol
-24hr urinary free cortisol
-Salivary cortisol
-Dexamethasone suppression test

Acromegaly

Dx: > IGF-1 and OGTT

Pituitary Tumor Surgery

- Indications:
  - Vision loss / double vision
  - Prolactinoma refractory to Dopamine agonist therapy
  - Progressively enlarging on serial images.
  - Cushing's disease / Acromegaly
  - Endocrinopathies
- Approach: "Below or above"?
  - **Transphenoidal**
  - Transcranial

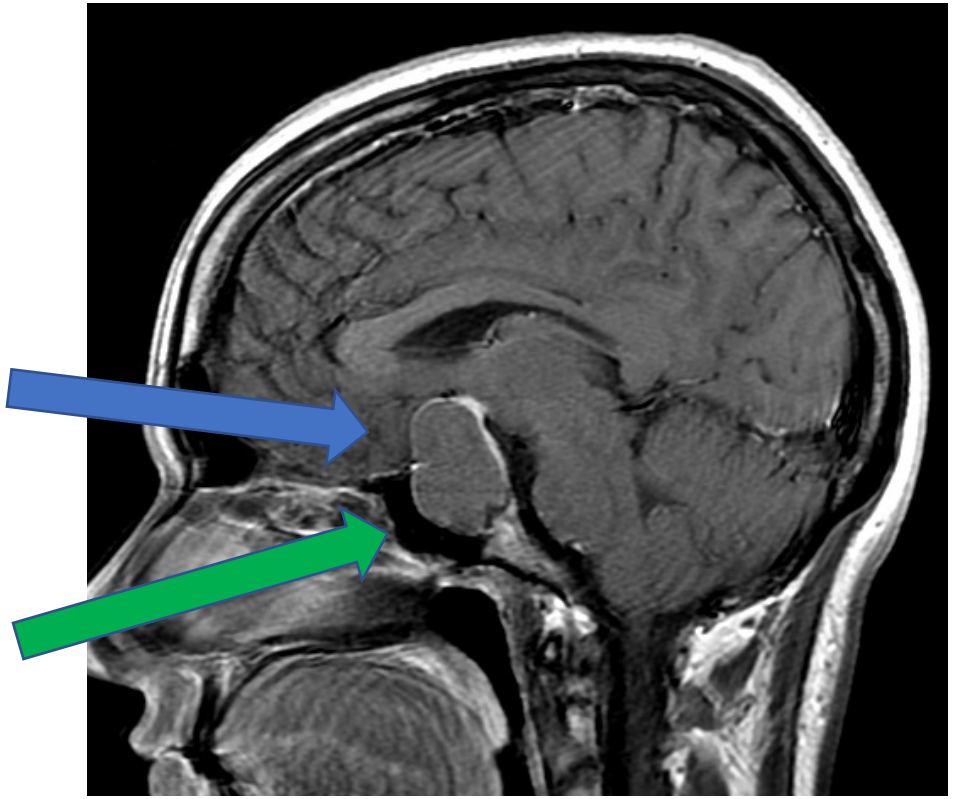

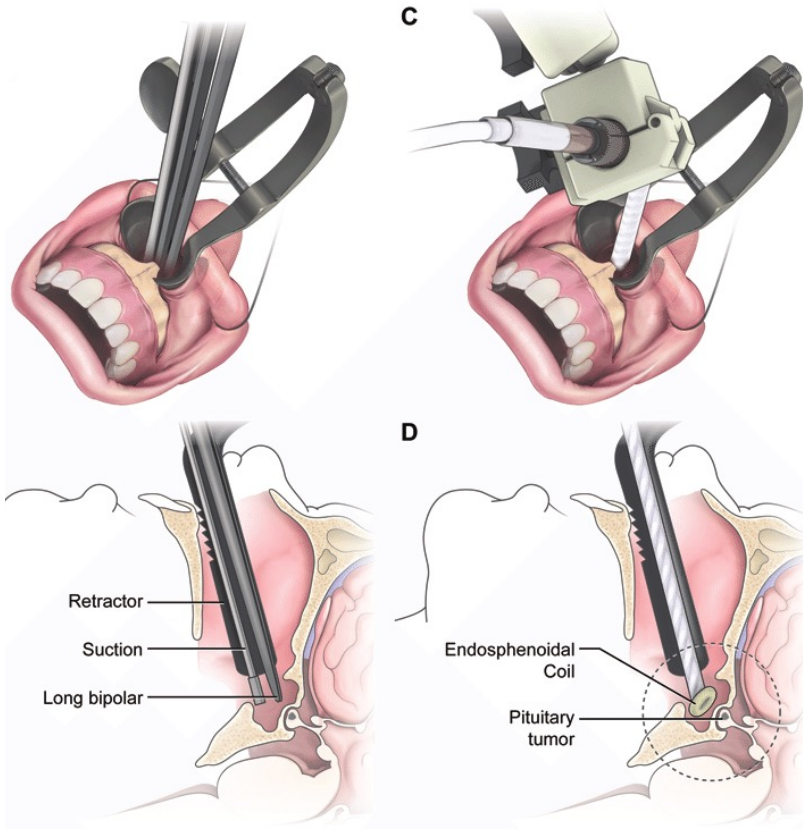

Sublabial Microscopic

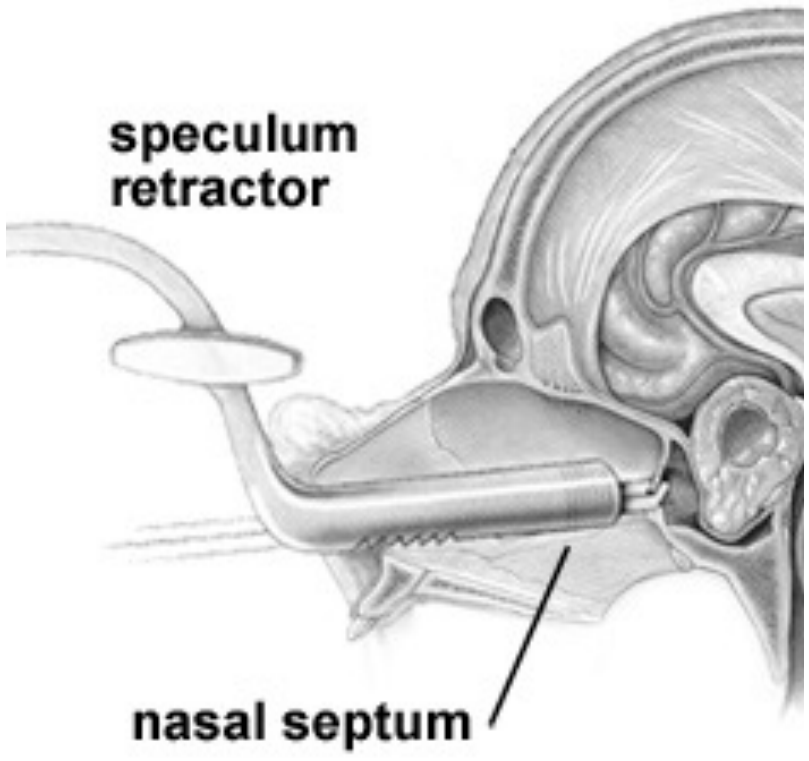

Endonasal Microscopic

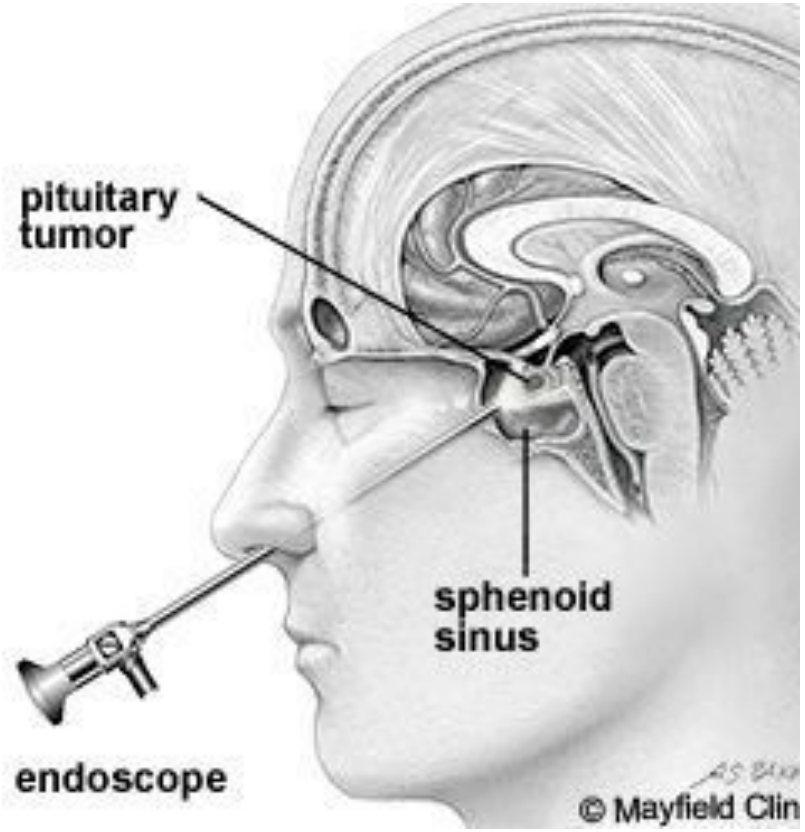

Endonasal Endoscopic

Transphenoidal Pituitary Surgery

ladvic.com

Endoscopic vs Microscopic View

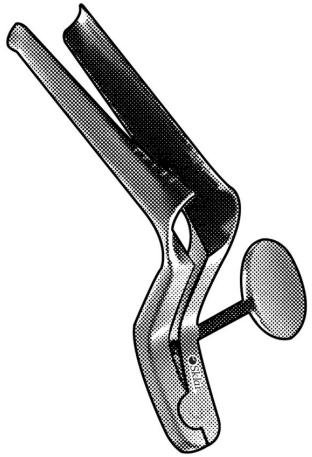

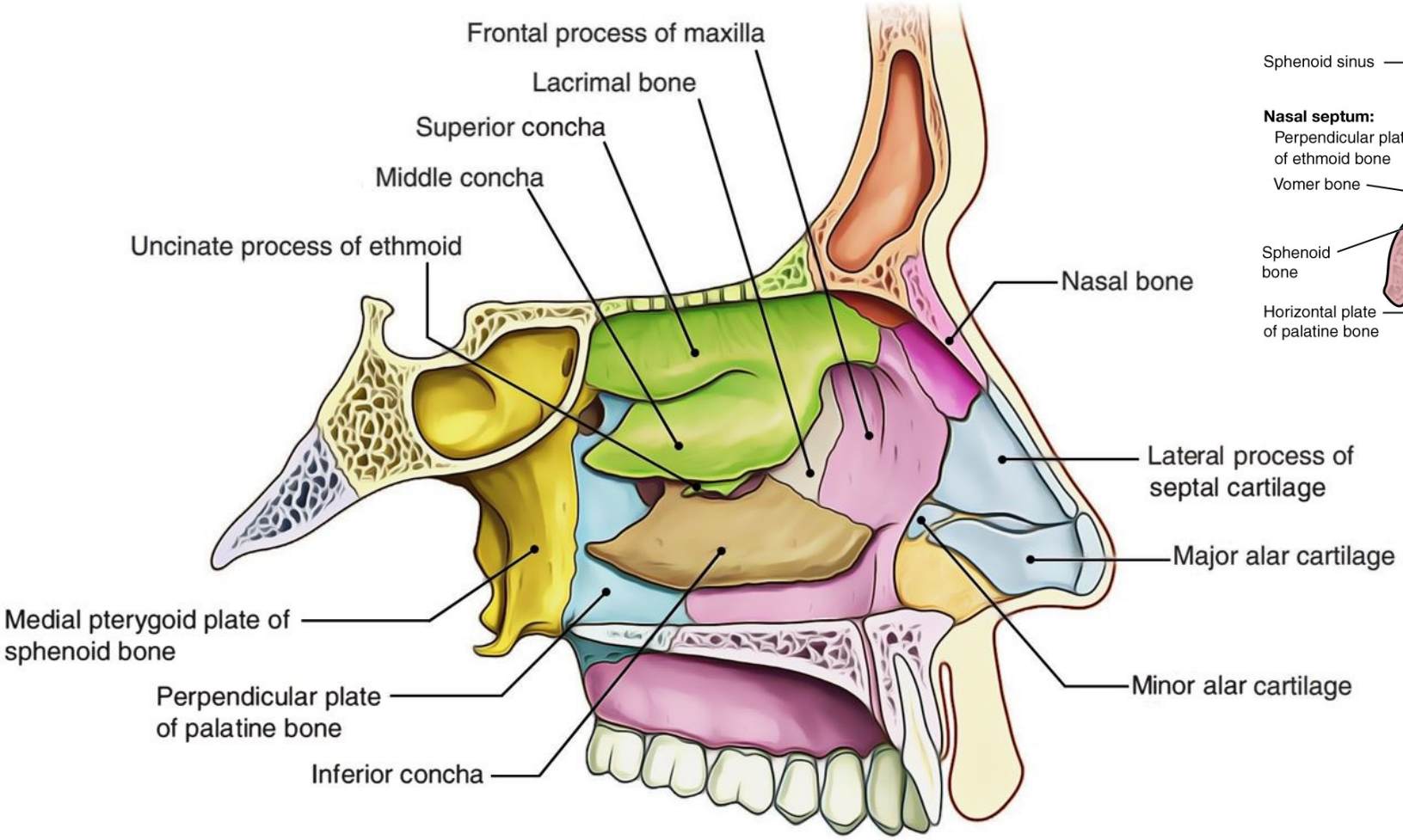

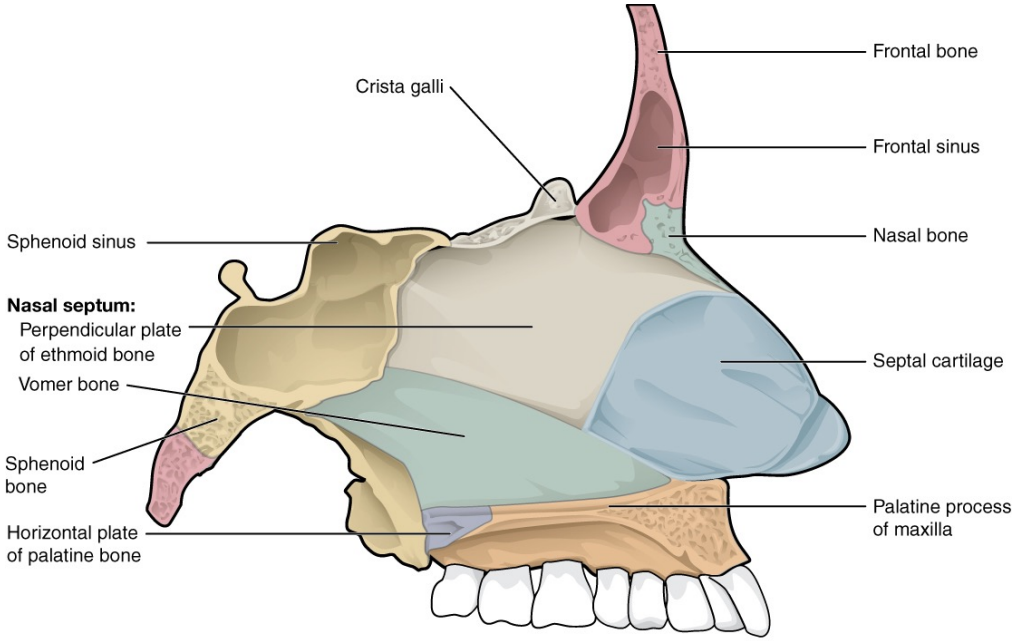

Sagittal section

Sinonasal Cavity Anatomy – Lateral Nasal Wall and Nasal Septum

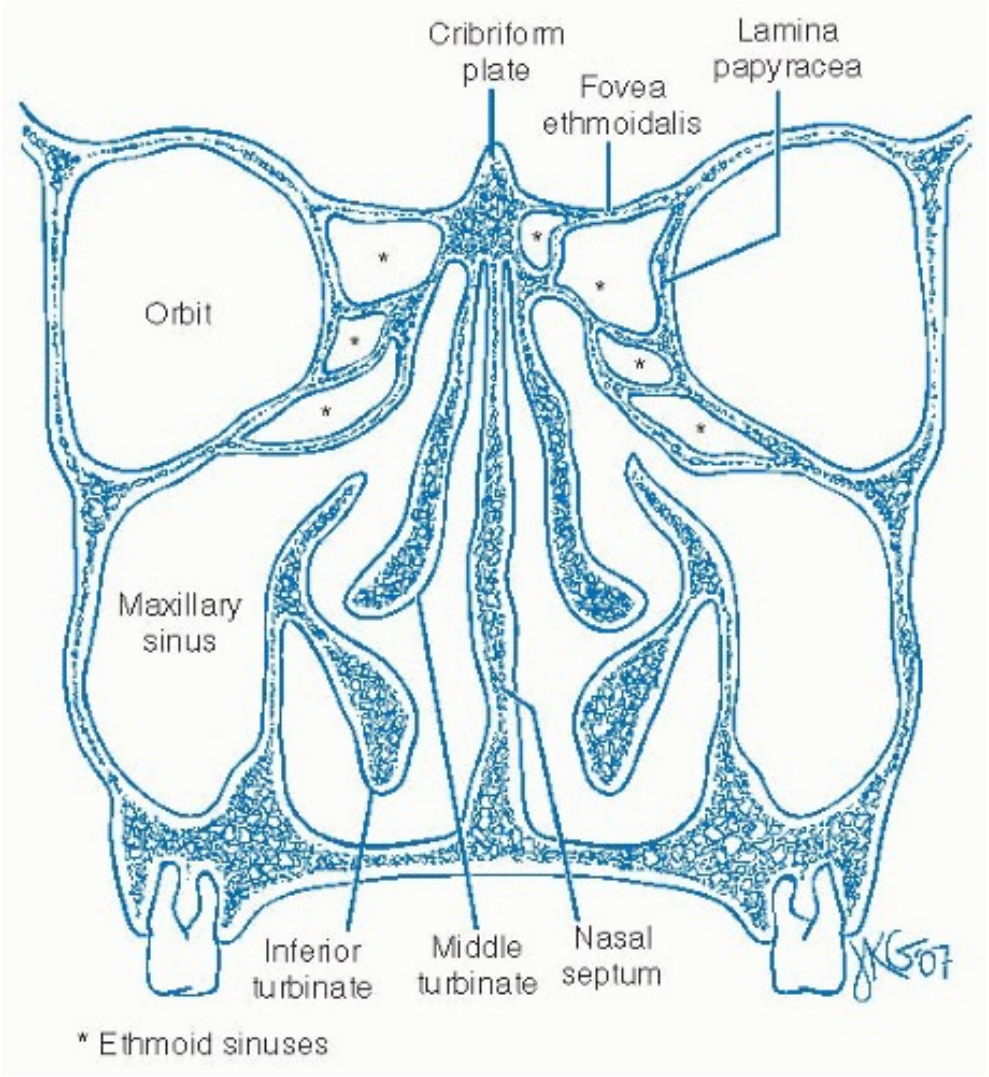

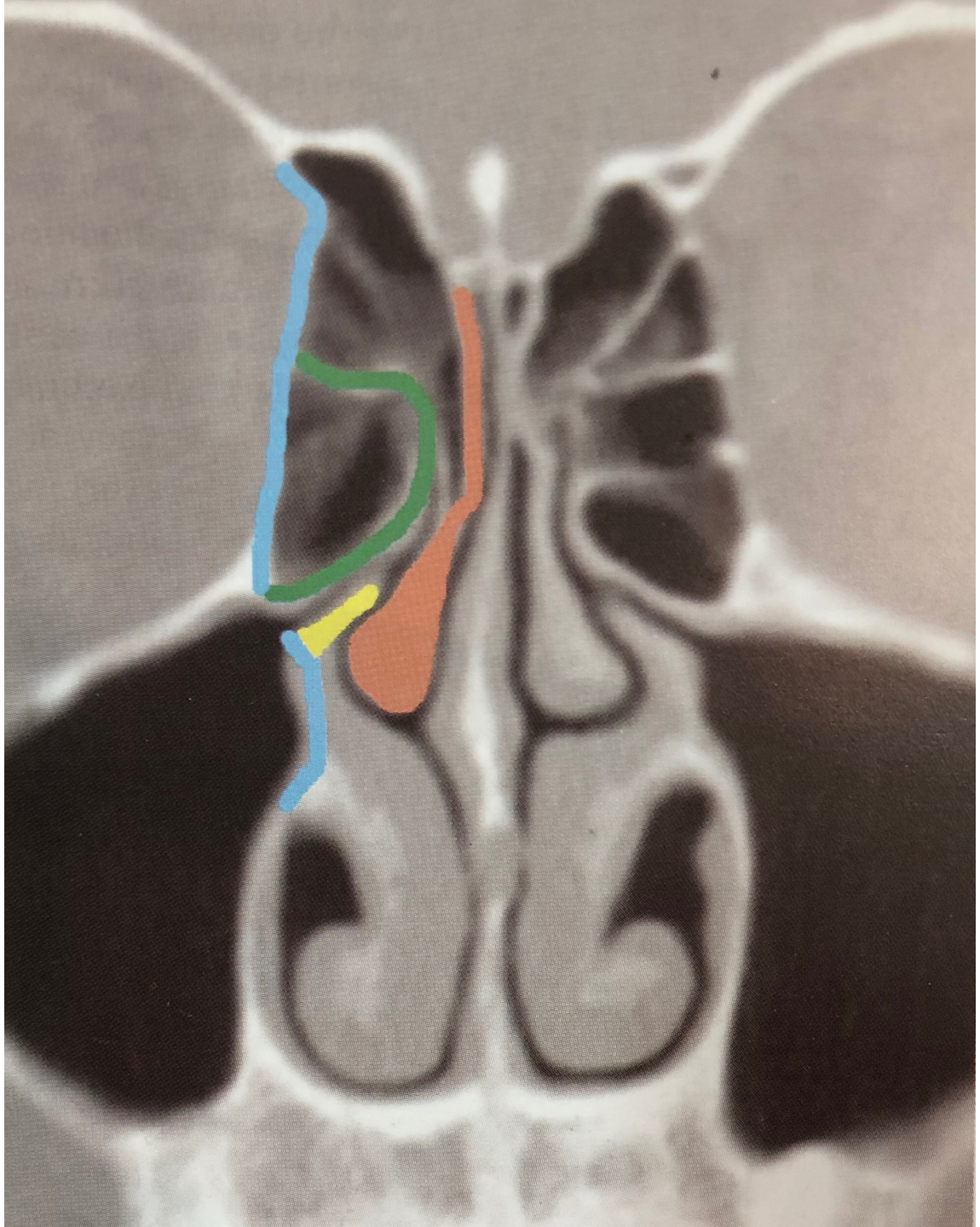

Ethmoid Bone & Turbinates

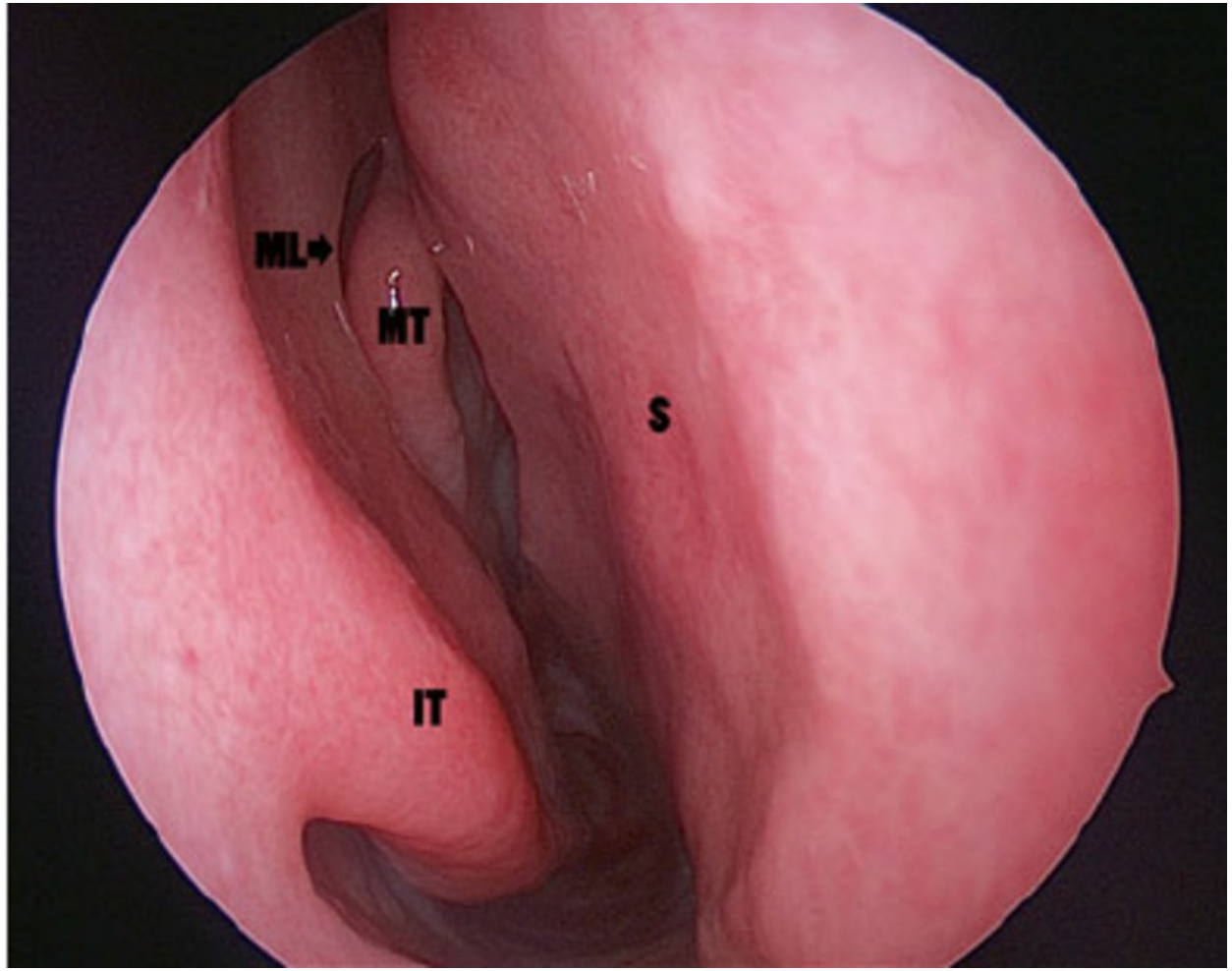
ML
MT
S
IT

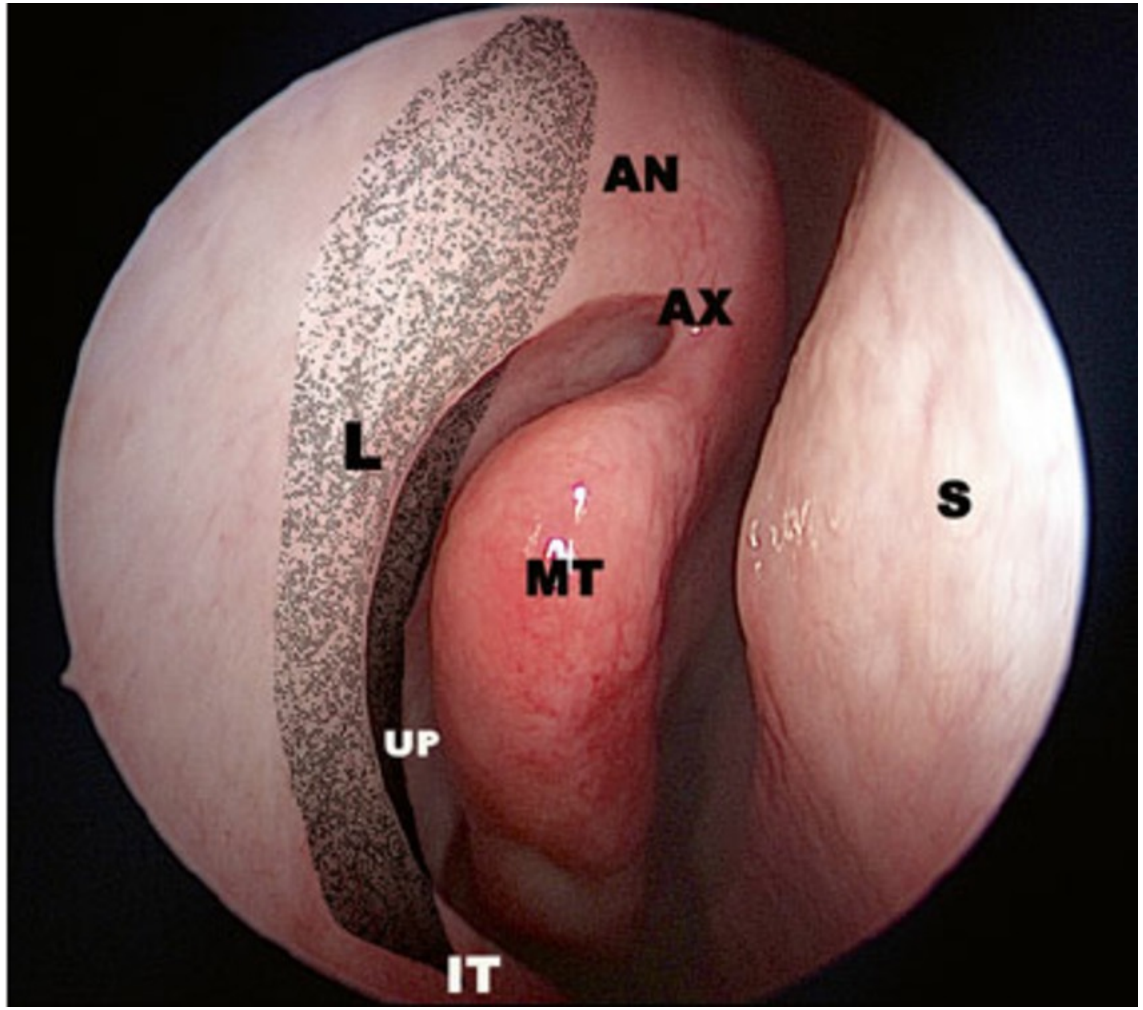
AN
AX
L
S
MT
UP
IT

Sphenoidotomy Technique

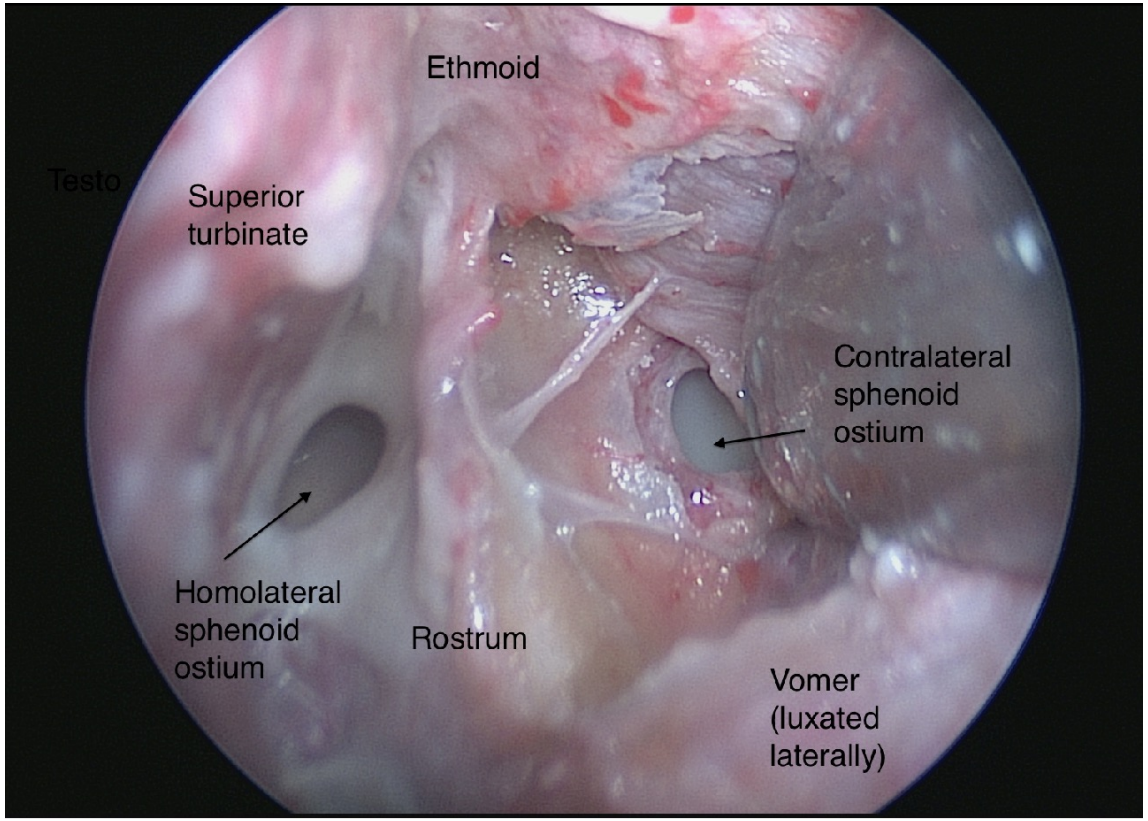

Approaches to the Sphenoid

Unilateral

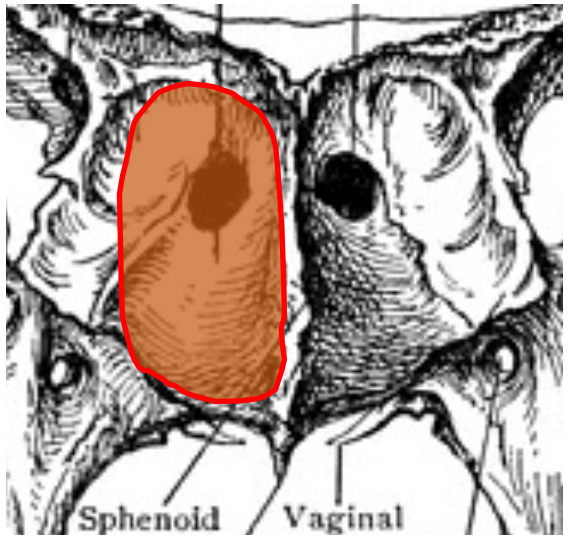

1.5 Approach

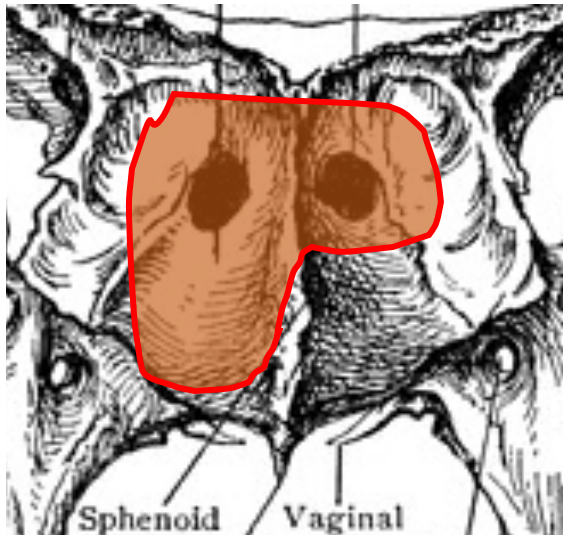

Bilateral Sphenoidotomies

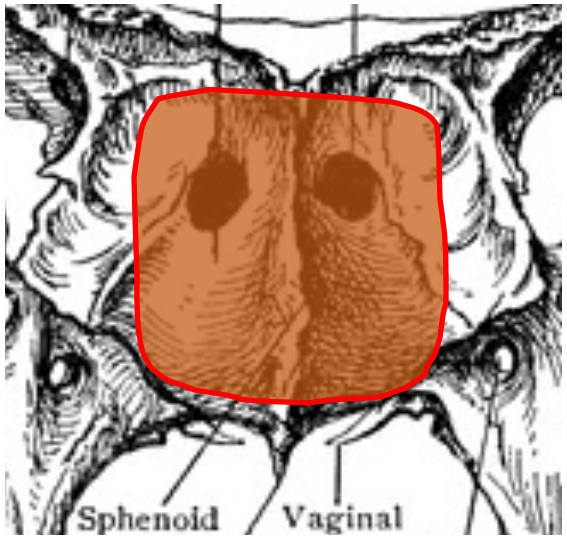

Thomas Jefferson Classification

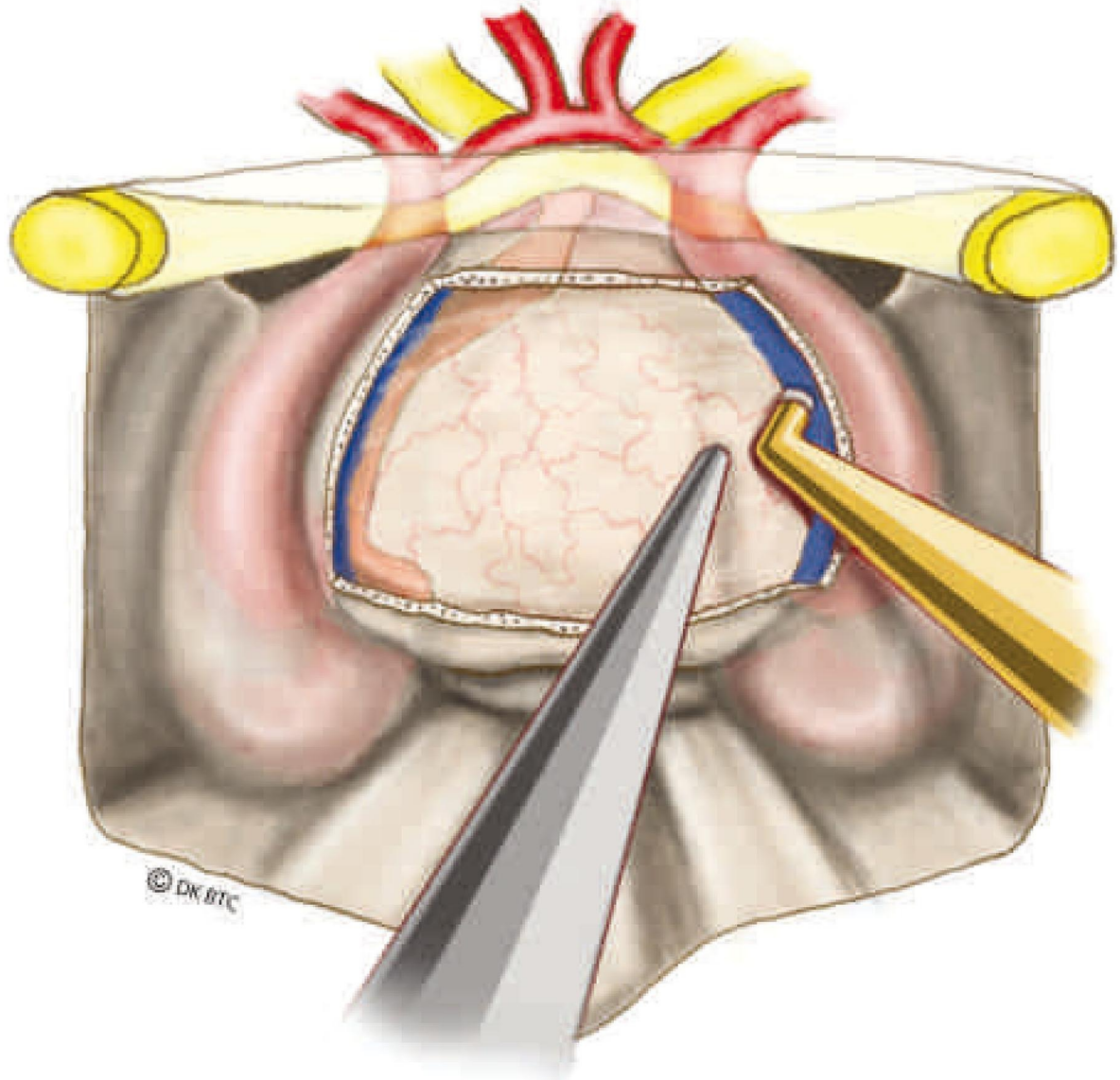

Sellar opening: CS to CS, up to tuberculum sellae.

Pituitary Macroadenoma

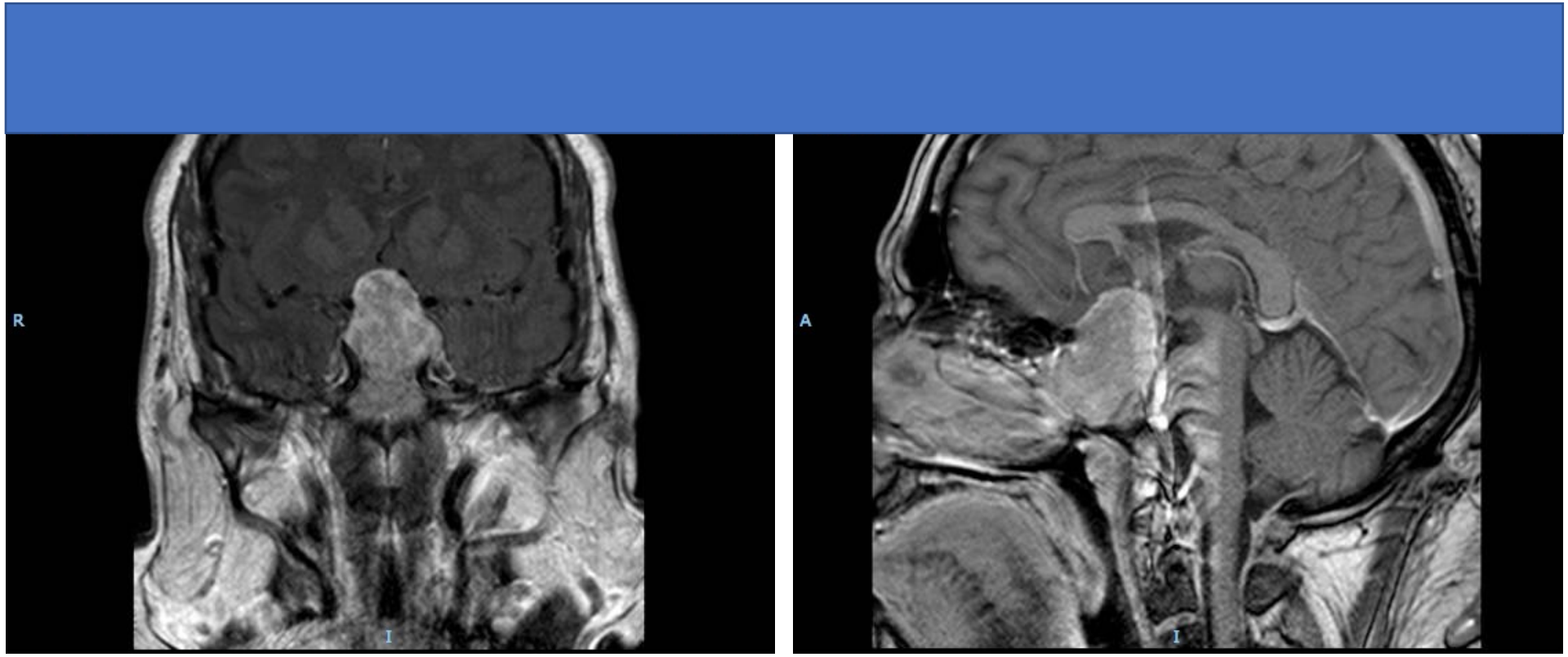

44y/o M with Hx of vision loss and headaches. PRL and rest of hormones WNLs.

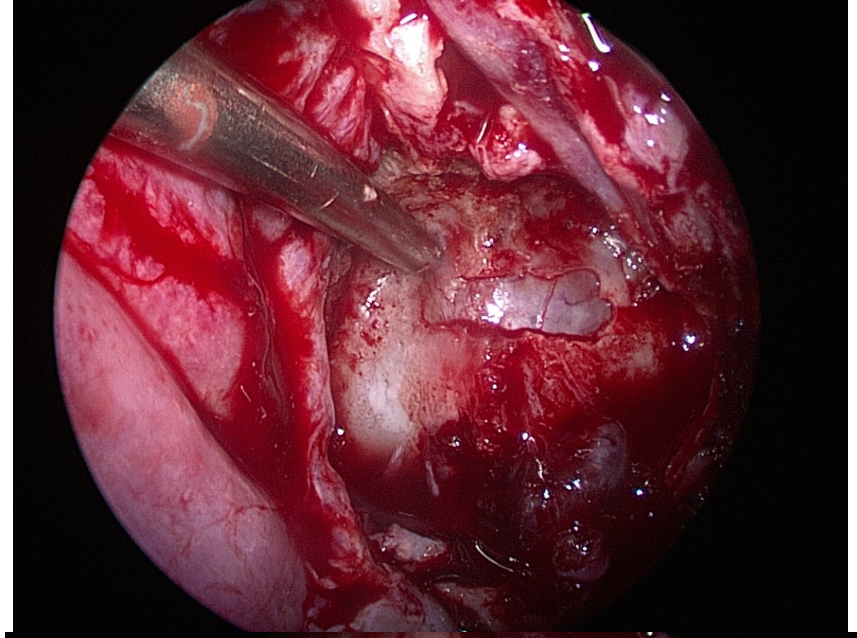

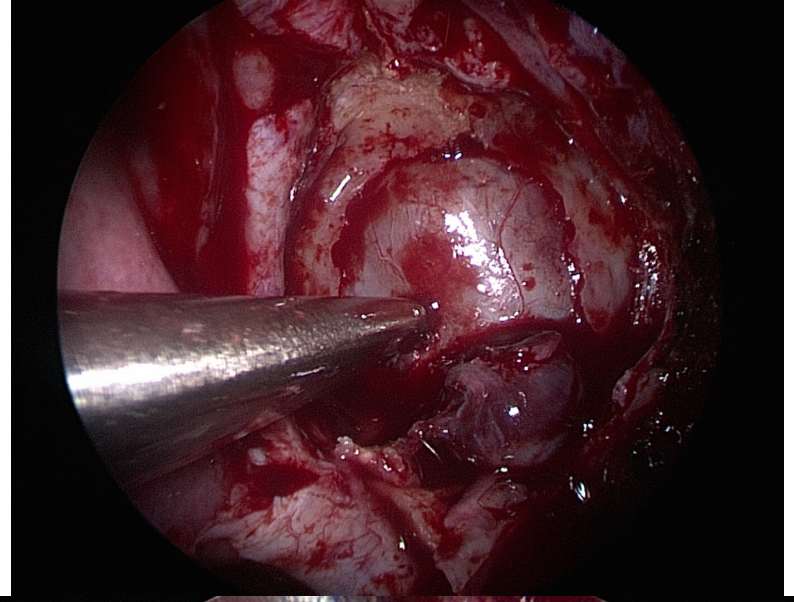

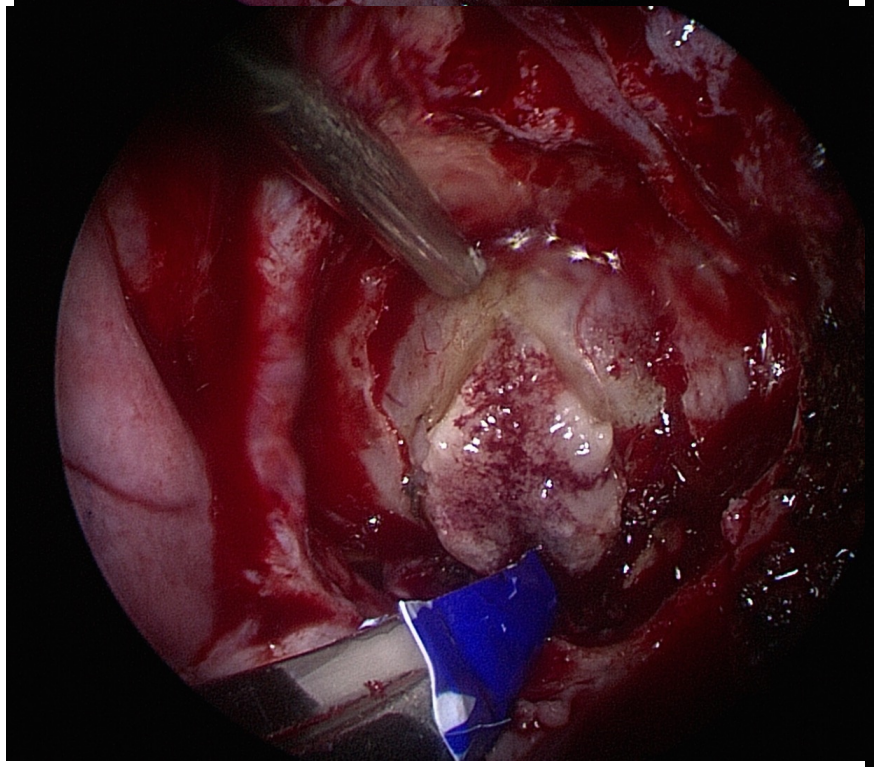

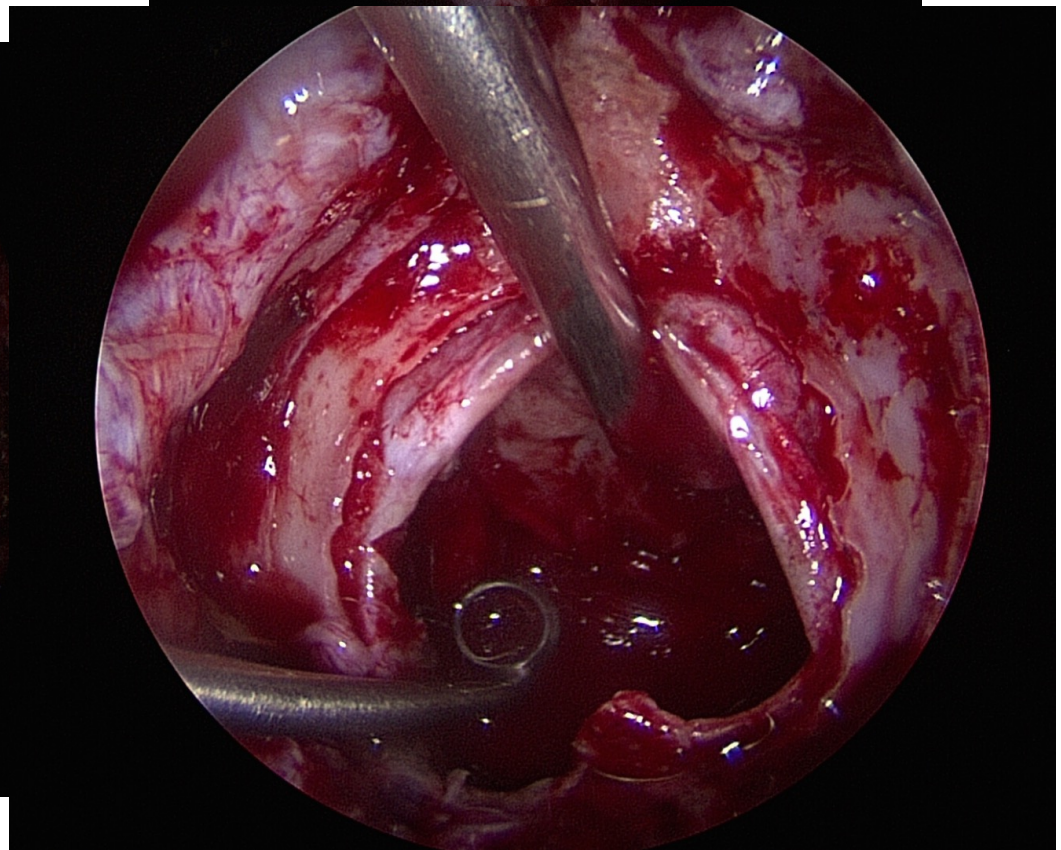

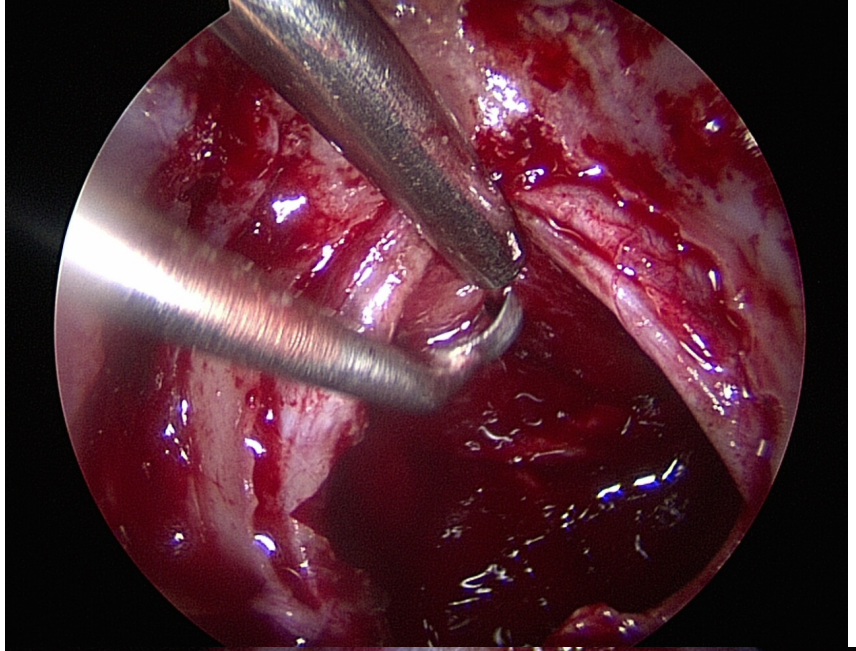

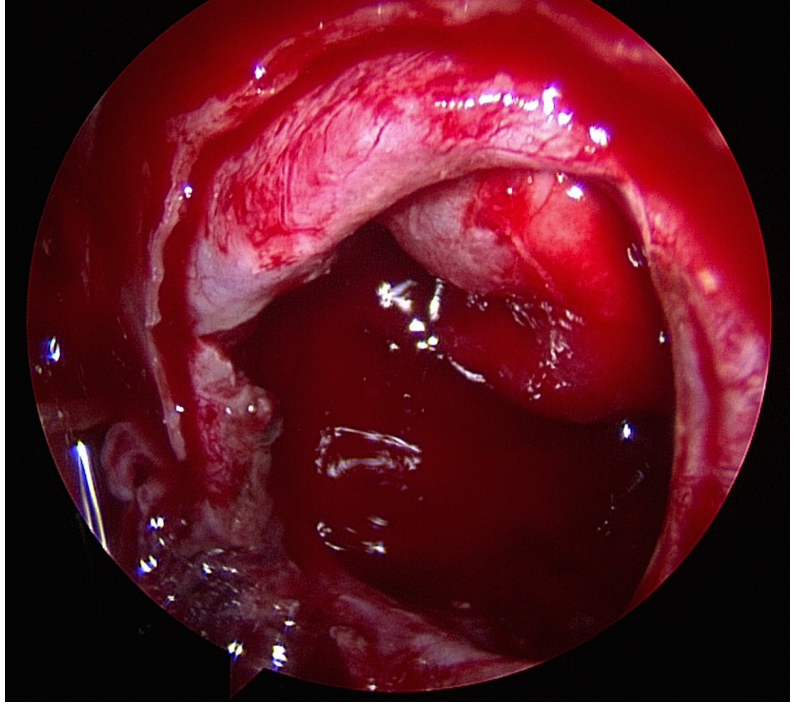

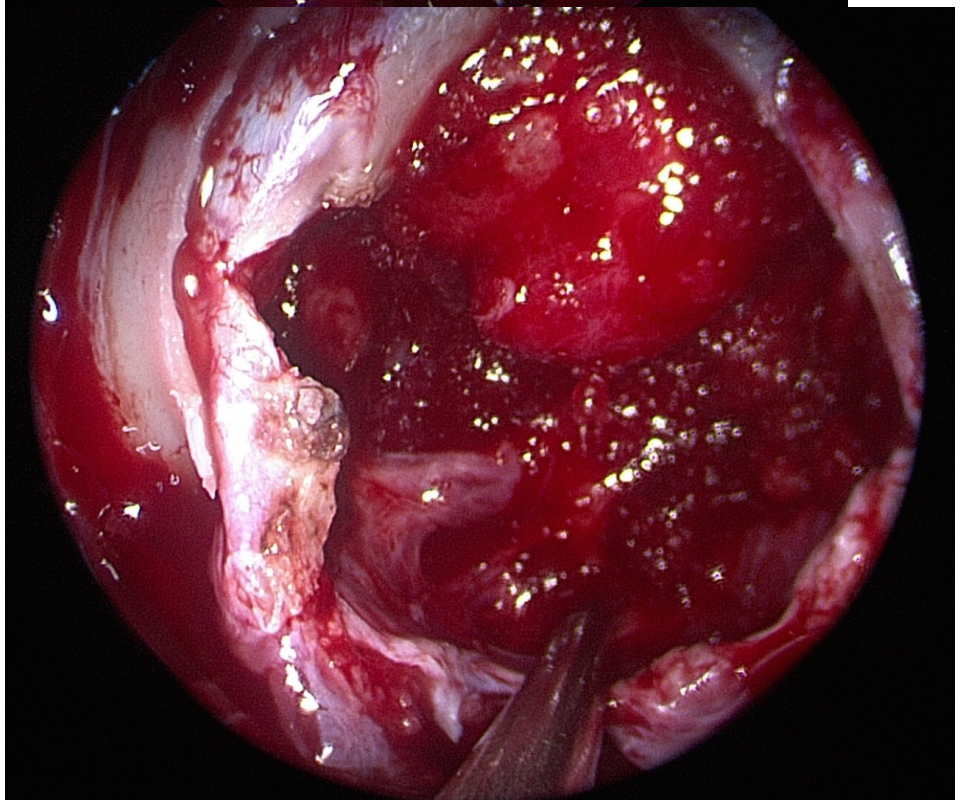

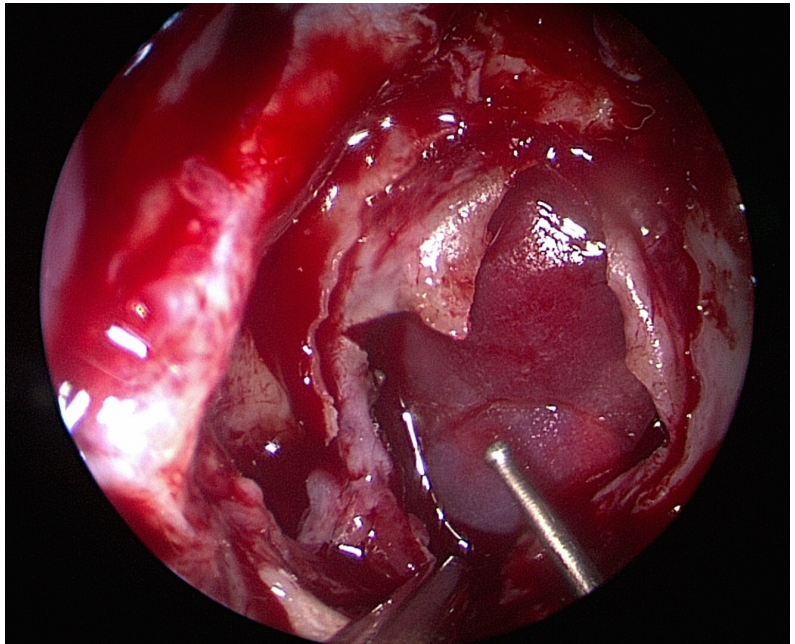

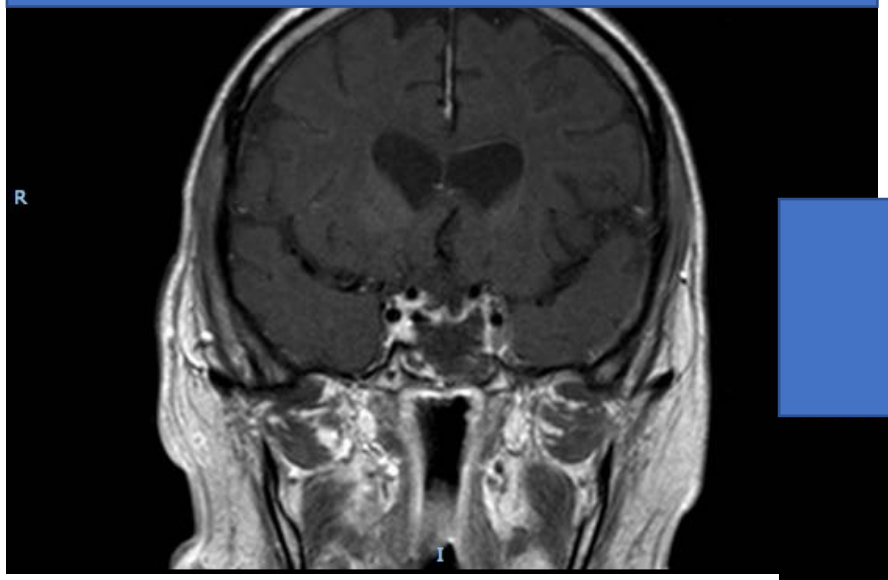
R
I

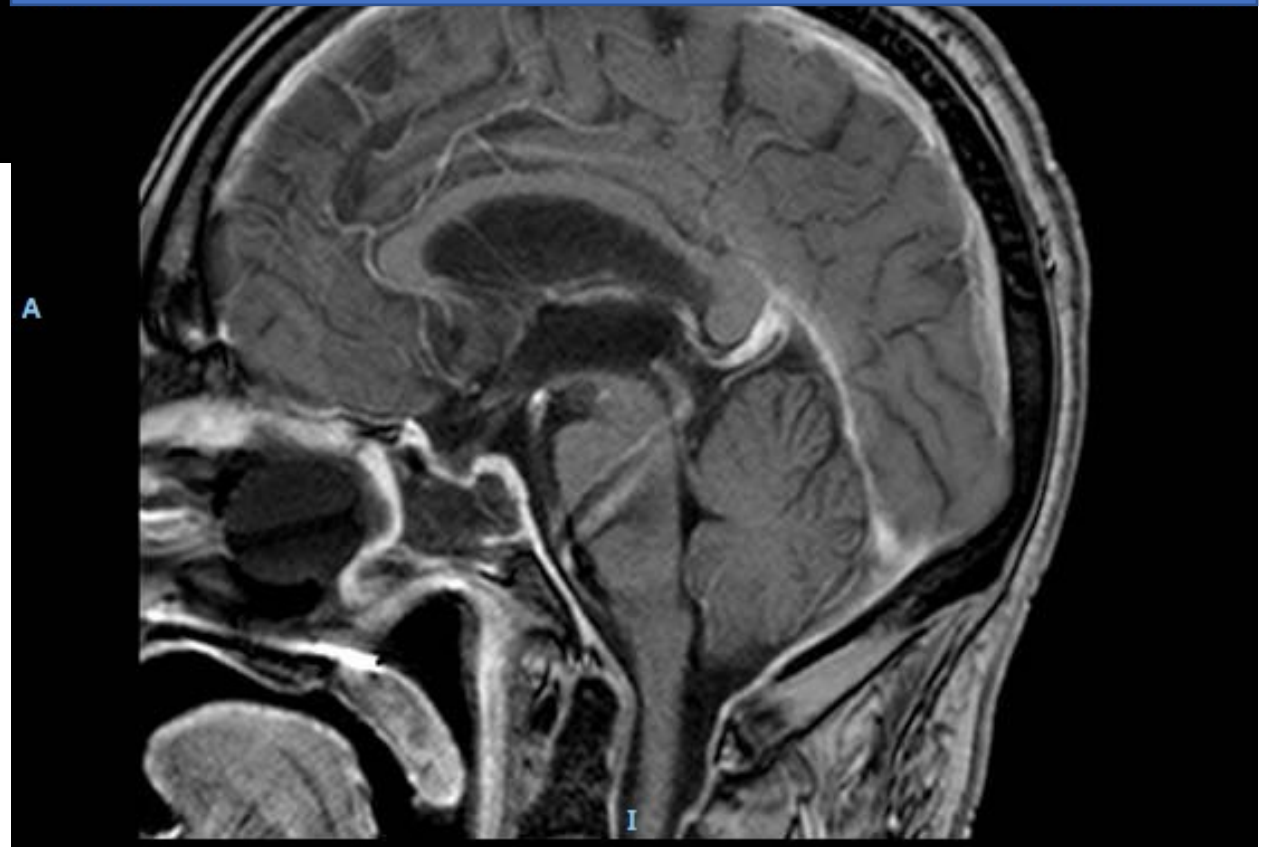
A
I

Sellar Closure

- No CSF leak, small dural defect: Surgicel
- No CSF leak, patulous diaphragm: **Inlay durepair + tissue sealant** (Tisseel, DuraSeal, Adherus)
- CSF leak:
  - Low flow and roof of sella: Inlay durepair + tissue sealant
  - Fishmouth/tuberculum sella: Inlay graft with nasoseptal flap.

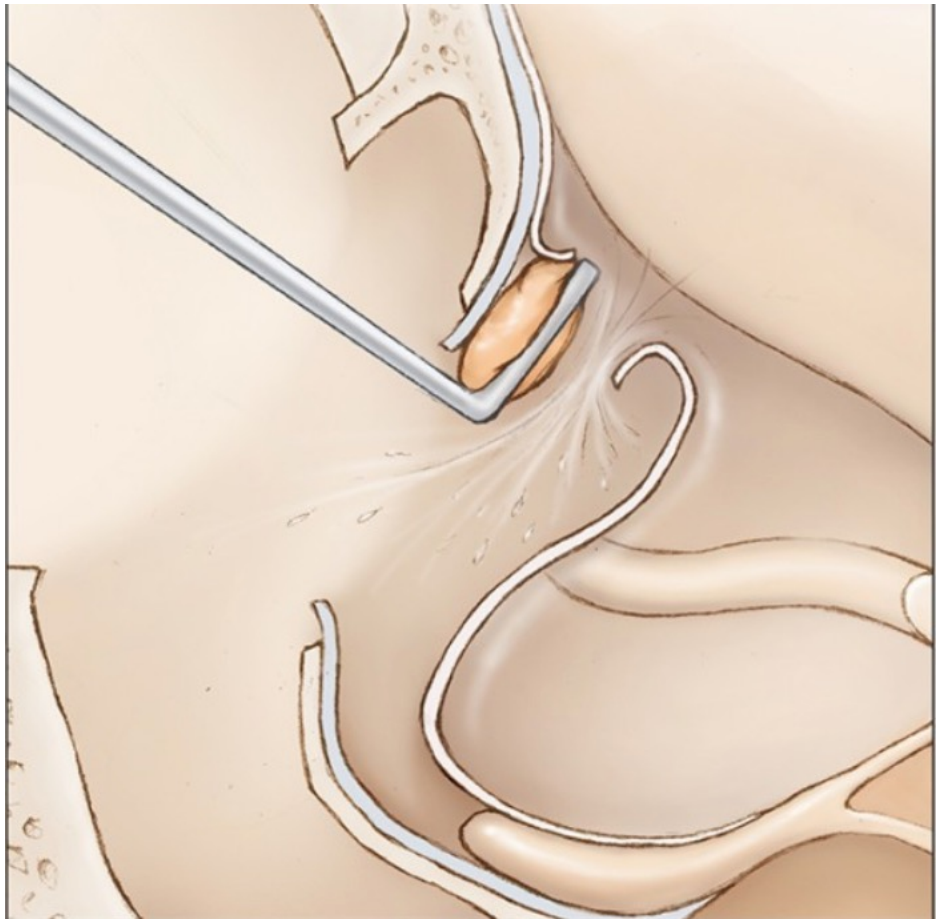

Post-Operative Care

- Neuro Step-Down
- HOB >45 degrees
- Ad lib PO H2O intake at bedside.
- Strict I/Os

- CSF leak watch:
  - CSF rhinorrhea
  - Post-nasal drip
  - Head CT: parasellar pneumocephalus
- DI watch
  - UO: > 350 x 2hrs
    - Check Na and spec grav
  - Spec grav </= 1.005
  - Rising Na level towards higher range of normal
  - DDAVP: nasal spray vs PO

Rathke’s Cleft Cyst

- Benign cystic remnants of the craniopharyngeal duct.
- Sellar & suprasellar region
- Majority of RCC’s are discovered incidentally
- Sx’s: H/As, endocrine dysfunction, visual loss; DI in 7-20% of patients

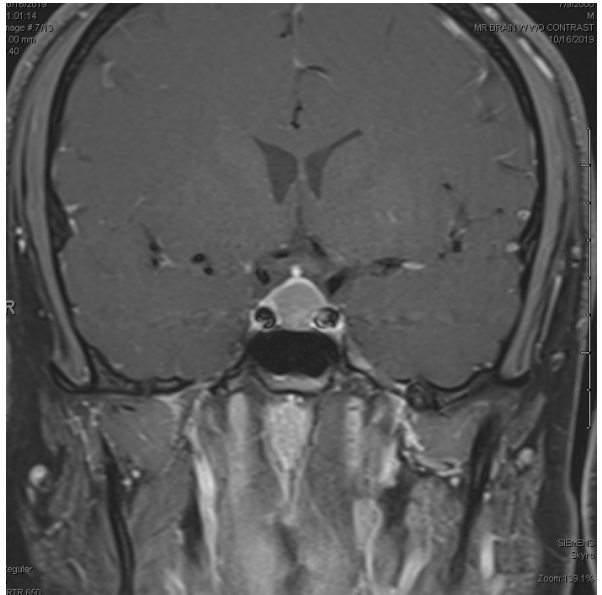

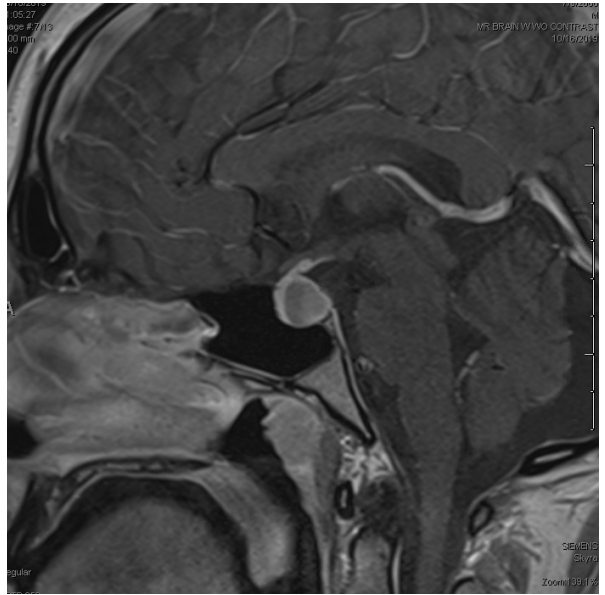

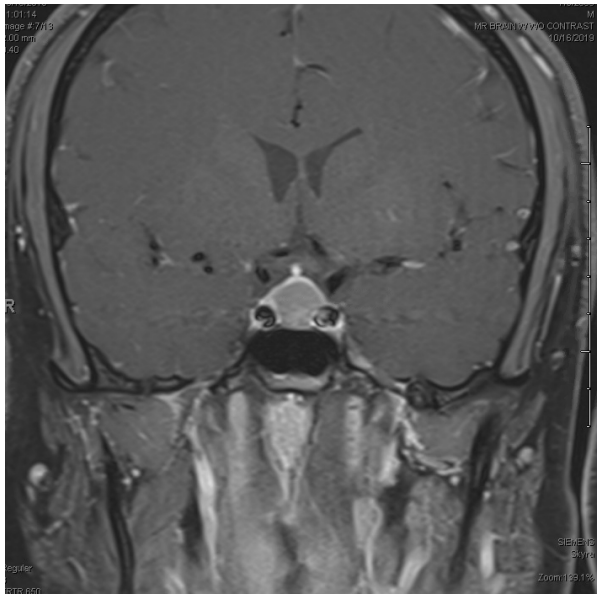

Rathke's Cleft Cyst Surgery

- Endoscopic transsphenoidal approach
- Wide fenestration and marsupialization of cyst
- Biopsy of wall prior to fenestration
- If CSF leak, repair as with pituitary adenoma.

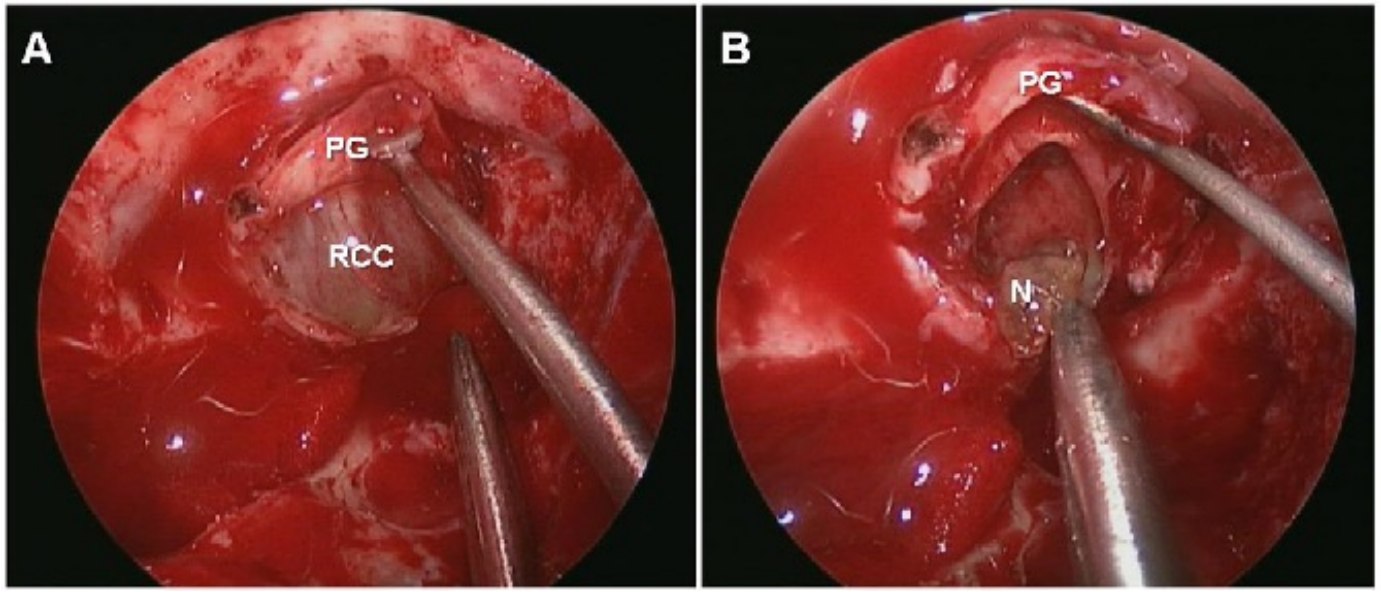

Craniopharyngioma

- Benign epithelial tumors that originate from the epithelial remnants of Rathke's pouch and the craniopharyngeal duct
  - WHO Grade I classification
- "Benign tumor in a malignant location"
- Local invasion of:
  - Hypothalamus
  - Optic chiasm
  - ICA, Pcom, hypophyseal arteries

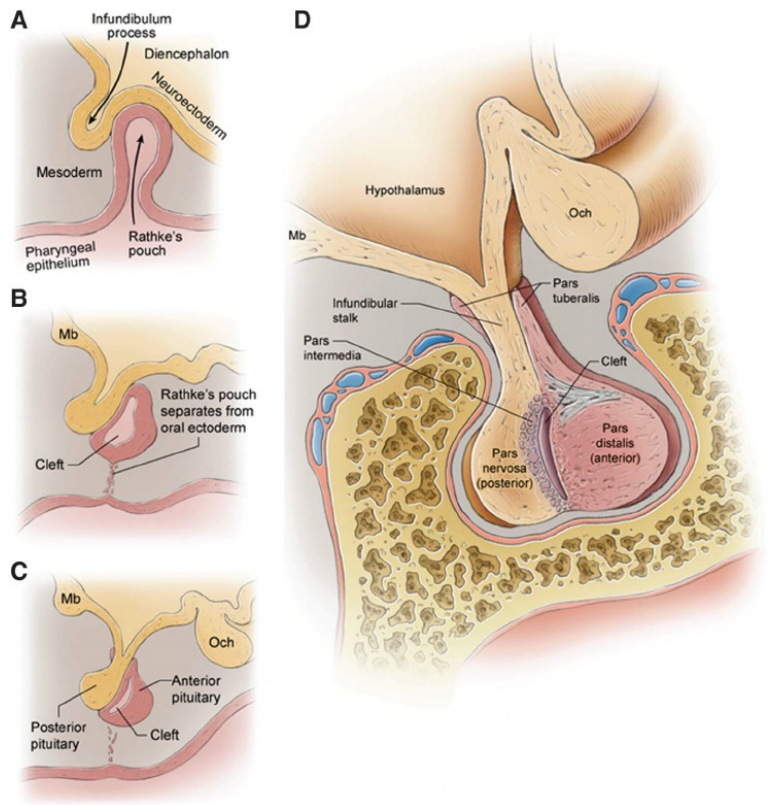

"To be sure, one may occasionally succeed in stripping out a thin-walled cyst, and examples of this have been reported, but when the tumor is partly solidified and calcareaous, sad experience warns the surgeon to <u>leave it pretty much alone</u>" –**Harvey Cushing, 1932**.

Radiographic Findings

- CT

- MRI

T2

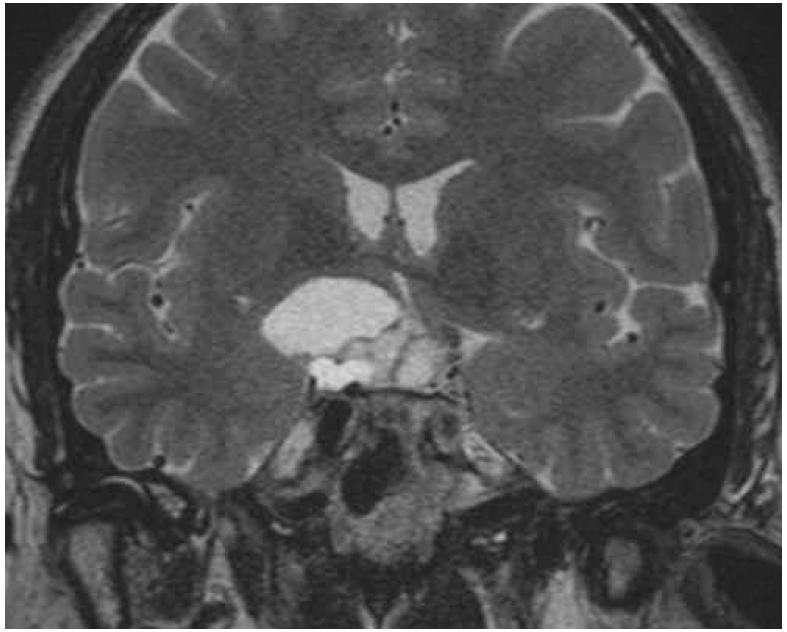

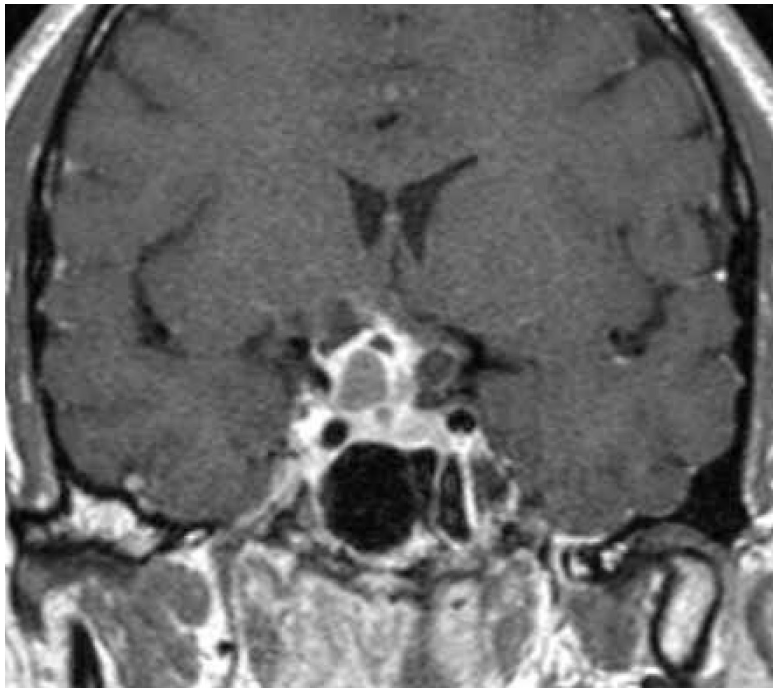

T1 + C

T1 - C

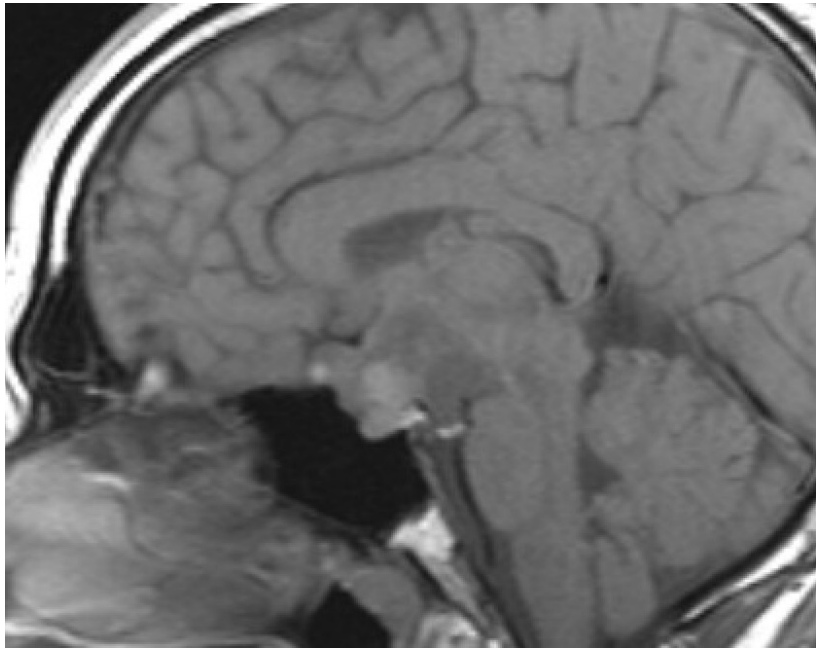

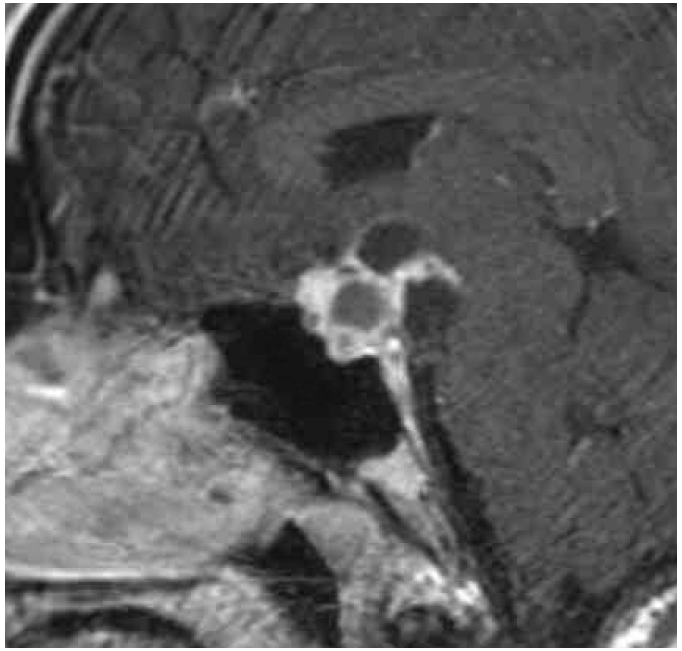

T1 + C

Craniopharyngioma Treatment

- **Surgical resection**
  - **Transcranial approach**
  - **Transphenoidal: expanded endoscopic approach (EEA)**
- Stereotactic radiotherapy
- Intra-tumoral radioactive isotopes
- Intracystic catheter placement for drainage
- Hormone supplementation

Expanded Endoscopic Approach

Advantages

- ”Minimally invasive”.
- Midline approach for a midline lesion
- No brain retraction.
- Better preserve chiasmal perforators.
- Better visual preservation

Limitations

- Steep learning curve
  - Extensive experience in endoscopic transsphenoidal surgery
  - Fellowship training
- Lack of space and/or 3D perception
- Difficult to reach lateral components
- CSF leak

Expanded Endoscopic Transphenoidal Approach

- Sellar approach + skull base removal (craniotomy)
- Craniopharyngioma: -> tuberculum sellae

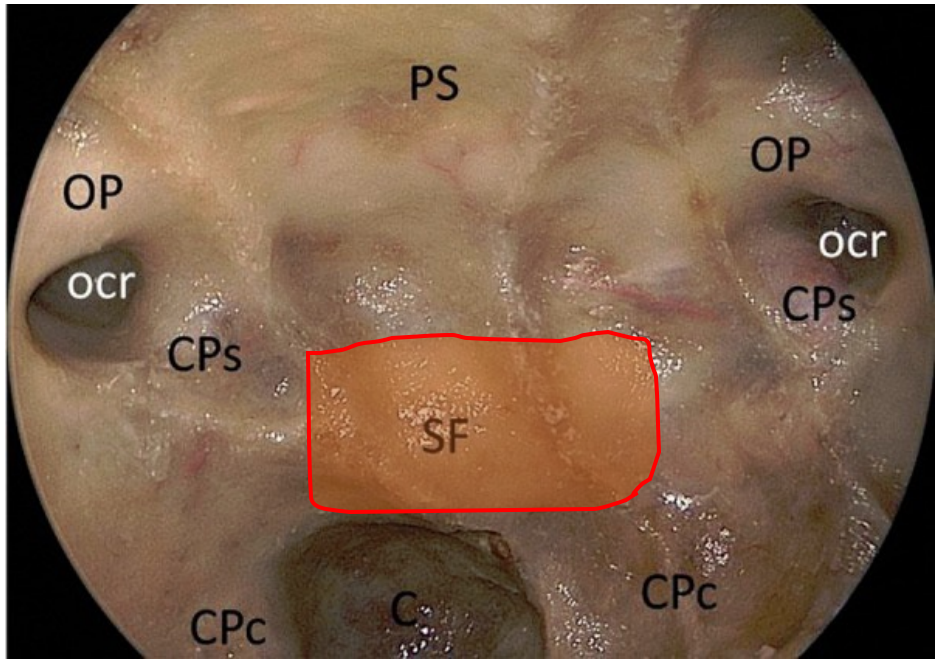

Sellar Approach

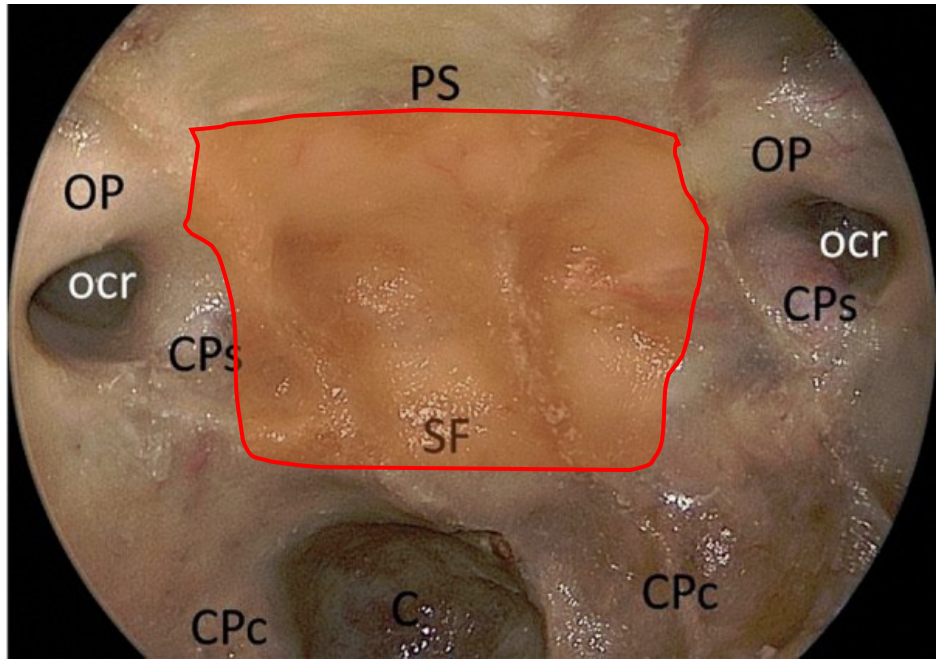

Expanded Approach - Transtubercular

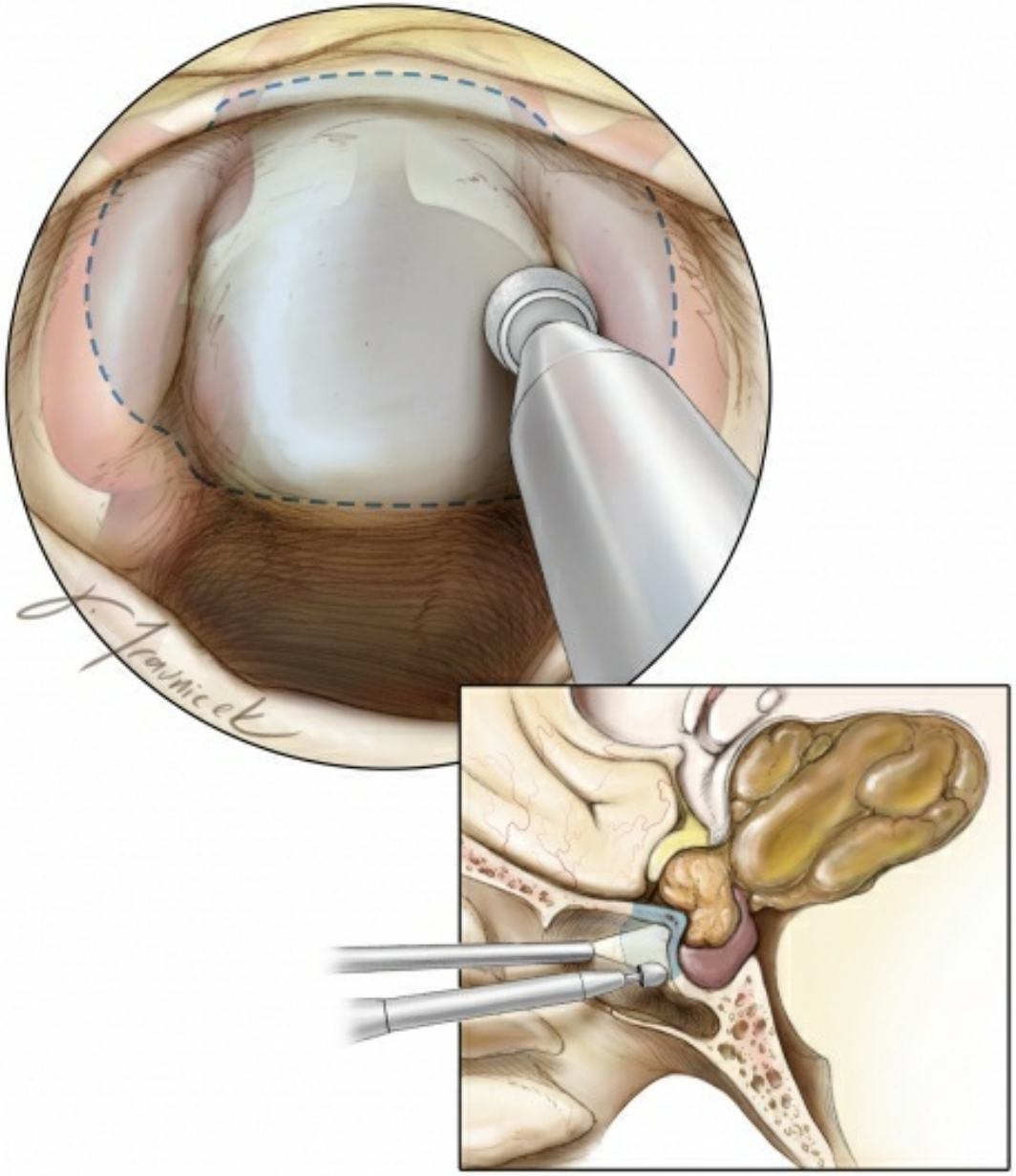
J. Travnicek

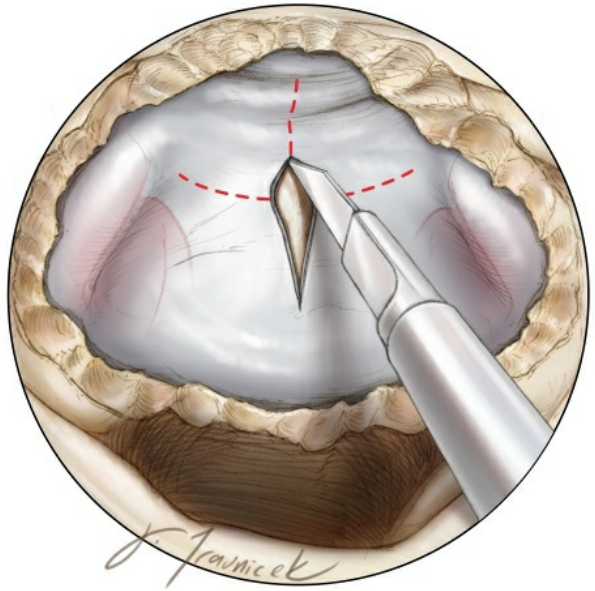
J. Travnicek


J. Travnicek

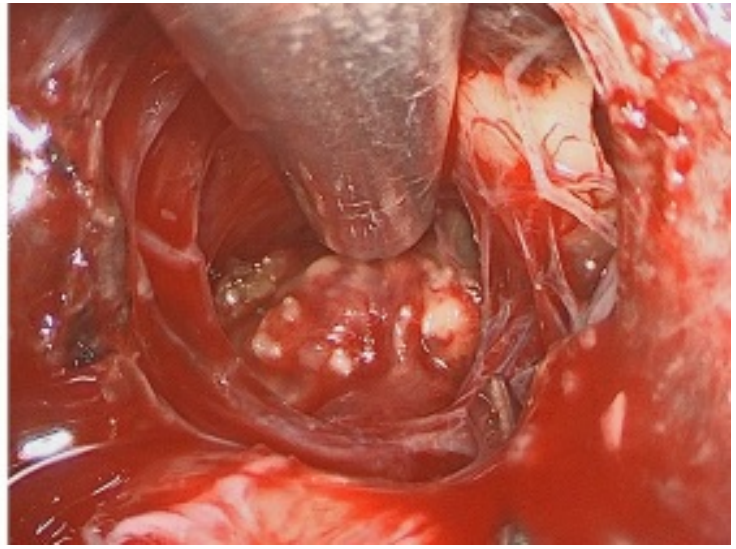

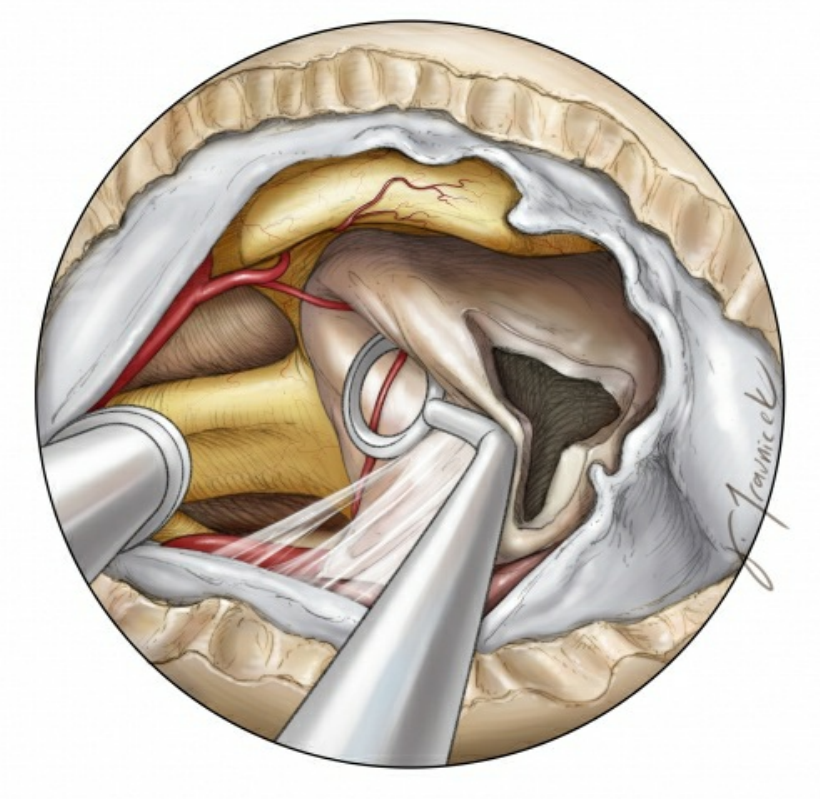

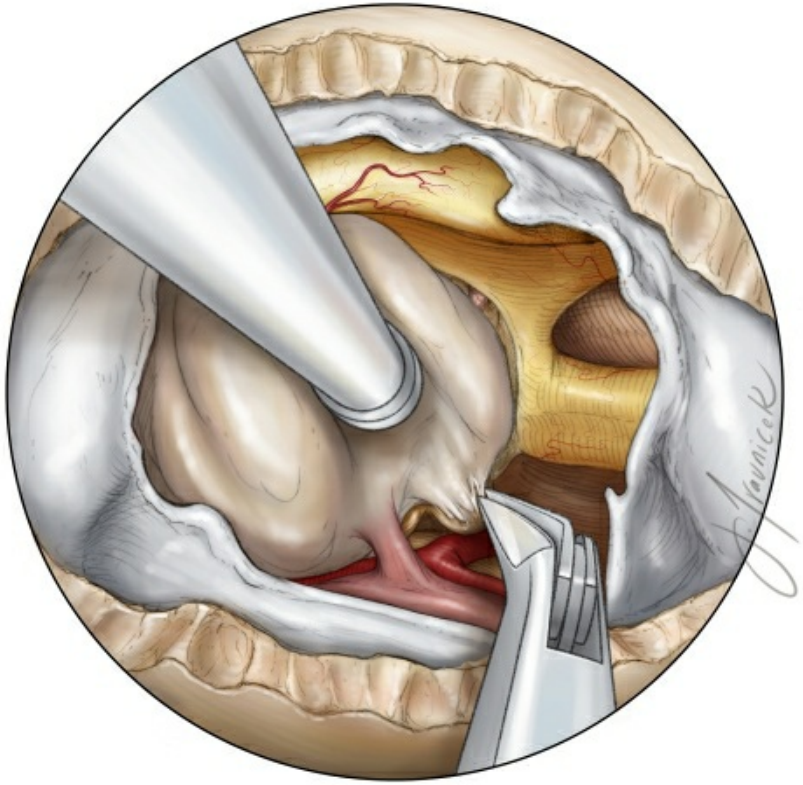

Skull Base Repair

- High rate of post-operative CSF leak (>30%) was a limiting factor for endoscopic skull base.
- With the development of the nasoseptal flap, the CSF leak rate has significantly dropped (<3%).
- Repair paradigm:
  - Dural repair: fascial lata button graft, gasket, inlay duragen + onlay dural substute
  - Nasoseptal flap.

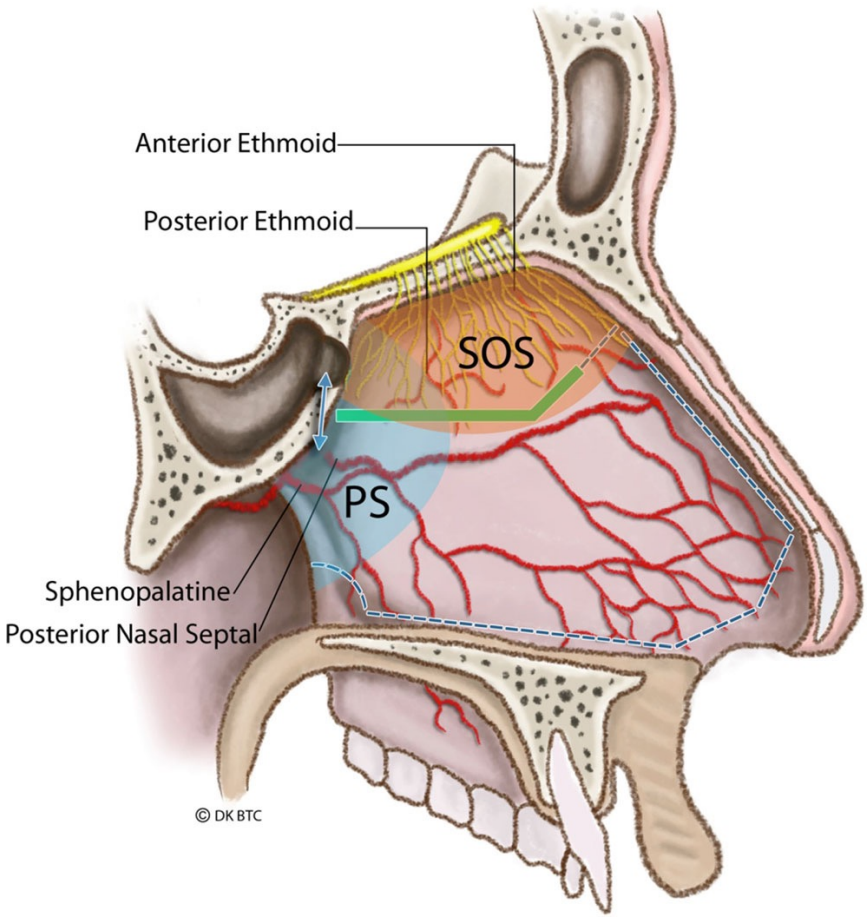

Nasoseptal Flap

- Pedicled mucosal flap
- Repair of high flow CSF leaks
- Expanded approaches

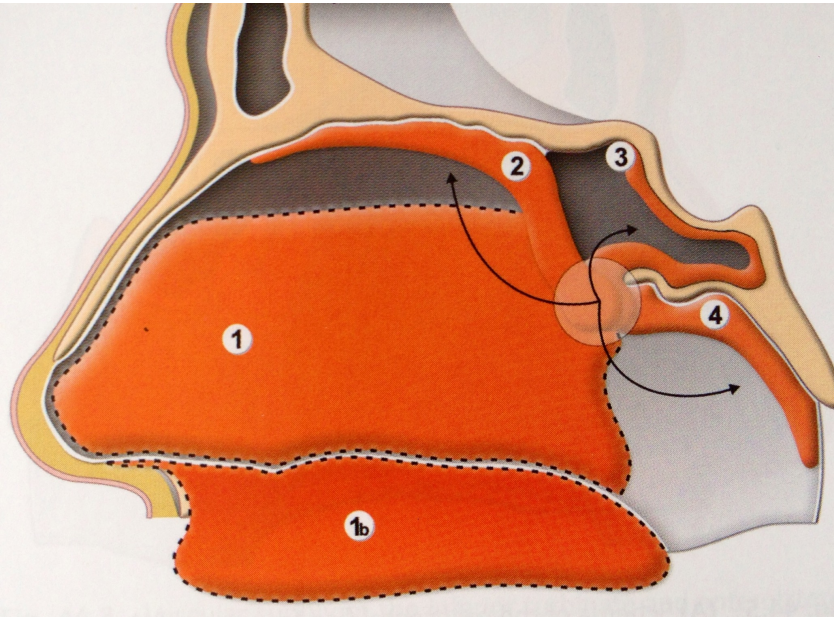

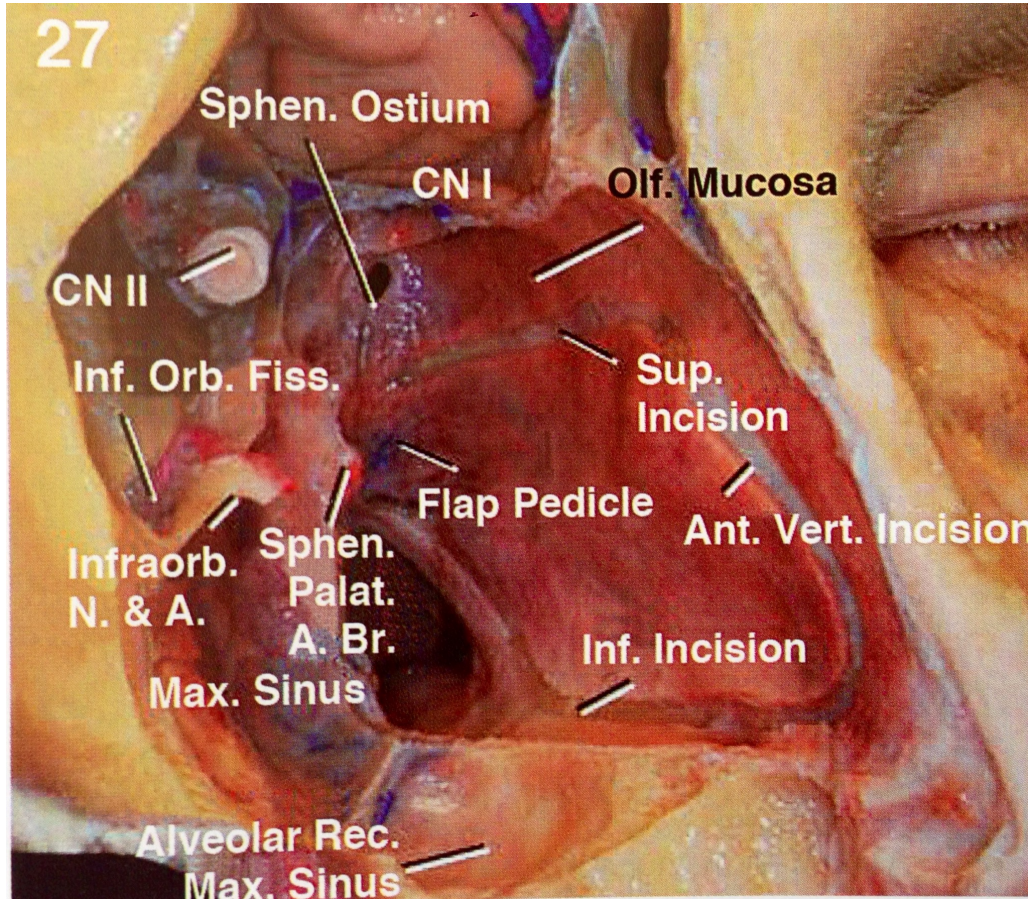

Ability to raise nasoseptal flap permits repair of large cranial base defects w/o craniotomy

The Laryngoscope

Endoscopic Repair of High-Flow Cranial Base Defects Using a Bilayer Button

Adam J. Luginbuhl, MD; Peter G. Campbell, MD; James Evans, MD; Marc Rosen, MD



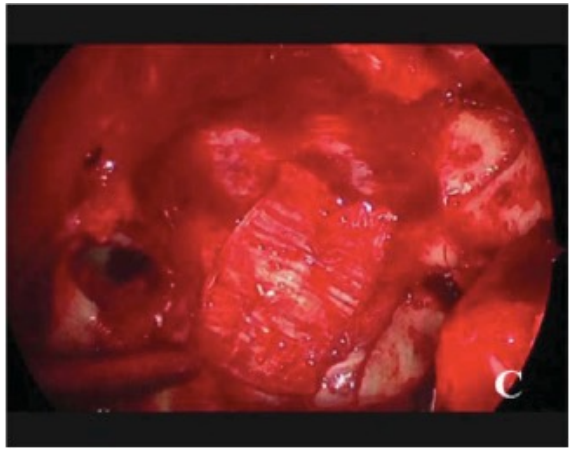

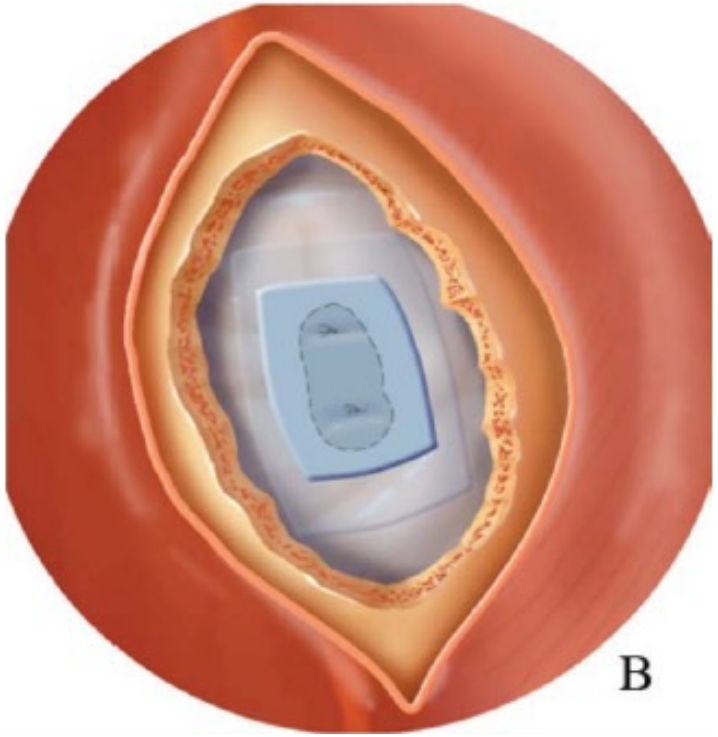

Gasket Repair

TJUH Experience

NEUROSURGICAL FOCUS

Neurosurg Focus 41 (6):E9, 2016

The learning curve in endoscopic endonasal resection of craniopharyngiomas

Varun R. Kshettry, MD,[1,3] Hyunwoo Do, MD,[1] Khaled Elshazly, MD,[1,4] Christopher J. Farrell, MD,[1] Gurston Nyquist, MD,[2] Marc Rosen, MD,[1,2] and James J. Evans, MD[1,2]

- 43 pts from 2005-2015
- Comparison of early and late cohorts to determine the learning curve of endoscopic approaches

TABLE 3. Surgical outcomes

Surgical Outcome	Total	Early (n = 20)	Late (n = 23)	p Value
Histological subtype*				
Adamantinomatous	29 (67%)	14 (74%)	15 (65%)	0.739
Papillary	13 (30%)	5 (26%)	8 (35%)	—
Extent of resection†				
STR	11 (26%)	8 (40%)	3 (13%)	0.078
NTR (>95%)	13 (30%)	8 (40%)	5 (22%)	0.193
GTR	19 (44%)	4 (20%)	15 (65%)	0.005
Complications				
New hydrocephalus	5 (12%)	4 (20%)	1 (4%)	0.167
Meningitis	2 (5%)	2 (10%)	0	0.210
CSF leak	9 (21%)	8 (40%)	1 (4%)	0.007
Hyponatremia	1 (2%)	0	1 (4%)	—
Seizure	1 (2%)	0	1 (4%)	—
Medical complications‡	6 (14%)	4 (20%)	2 (9%)	0.393
Rhinological complications§	8 (19%)	4 (20%)	4 (17%)	—
Carotid artery injury	1 (2%)	1 (5%)	0	0.465
Stroke	1 (2%)	1 (5%)	0	0.465
Median length of stay (days)	6	6	6	—
Discharge status¶				
Home	30 (83%)	9 (64%)	21 (95%)	0.024
Rehabilitation or nursing facility	6 (17%)	5 (36%)	1 (5%)	—

TABLE 4. Postoperative visual outcome*

Visual Outcome	Total	Early (n = 20)	Late (n = 23)	p Value
Improved	31 (84%)	14 (88%)	17 (81%)	0.680
Normalized	9 (24%)	6 (38%)	3 (14%)	—
Stable	5 (14%)	1 (6%)	4 (19%)	—
Worse	1 (3%)	1 (6%)	0	—

“Eyebrow” Supra-Orbital Craniotomy

- “Sweet-spot” parasellar lesions

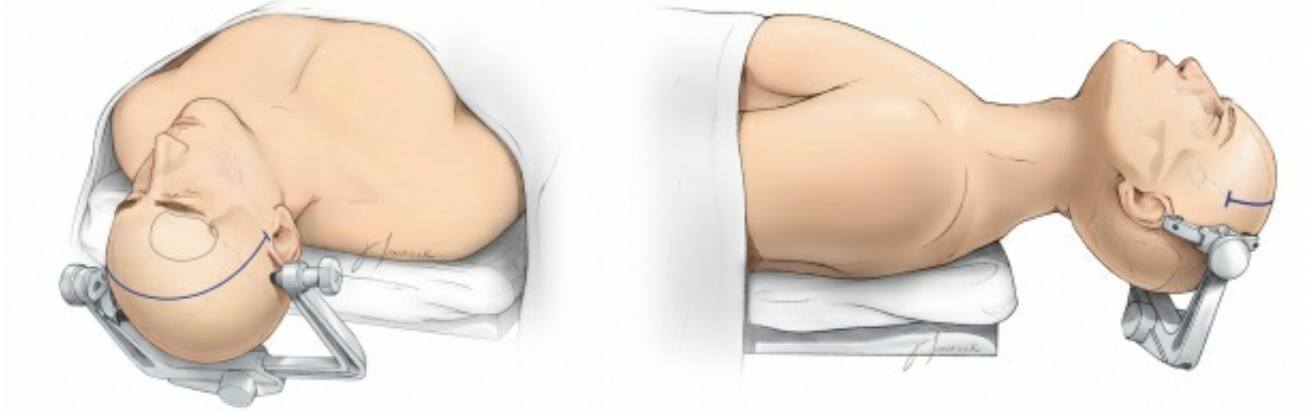

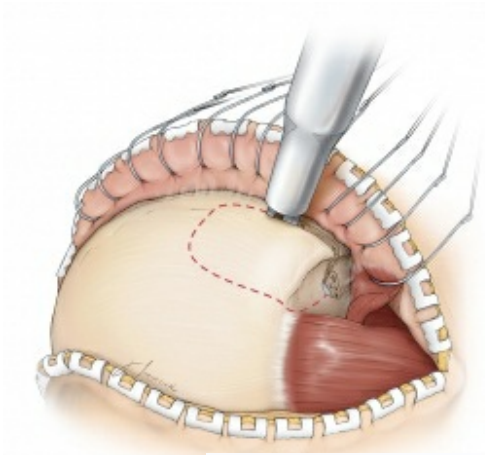

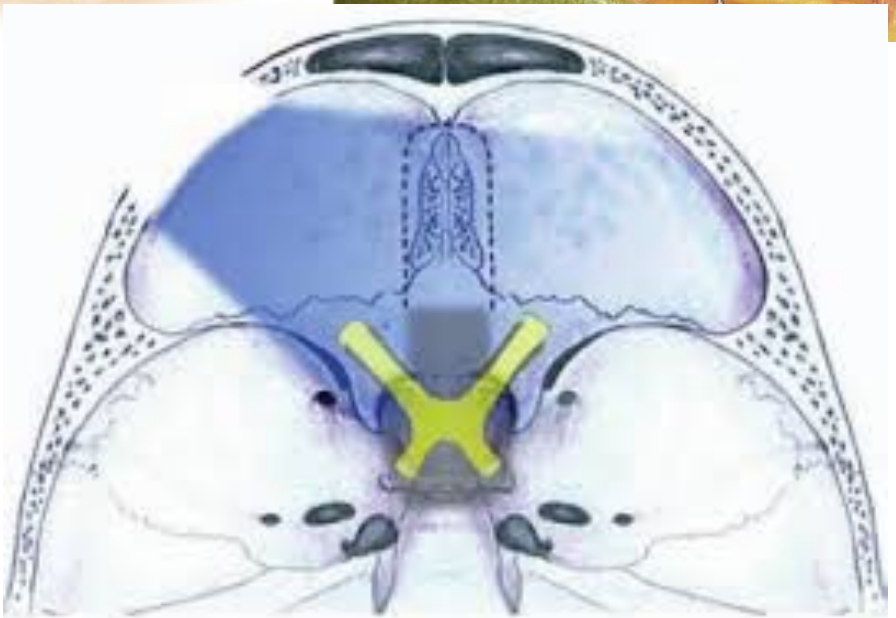

Conclusion

- Endoscopic skull base surgery offers a less invasive approach for safe resection of pituitary region tumors.
- Requires a multidisciplinary team.
- Steep learning curve therefore fellowship training is essential.
- Its limitations should be acknowledged.
- Use of endoscope can lead to less invasive open transcranial approaches by offering a wider angle of view.

References

- Jahangiri A, Wagner JR, Han SW, et al. *Improved Versus Worsened Endocrine Function After Transsphenoidal Surgery for Nonfunctional Pituitary Adenomas: Rate, Time Course, and Radiological Analysis.* JNeurosurg*. 2016 Mar;124(3):589-95.*
- Jho DH, Biller BM, Agarwalla PK. Pituitary Apoplexy: Large Surgical Series With Grading System. World Neurosurg. 2014 Nov;82(5):781-90.
- Lau D, Rutledge C, Aghi MK. Cushing's Disease: Current Medical Therapies and Molecular Insights Guiding Future Therapies. Neurosurg Focus. 2015 Feb;38(2)
- Paluzzi A, Fernandez-Miranda JC, Stefko ST, et al. *Endoscopic Endonasal Approach for Pituitary Adenomas*. Pituitary 2014 Aug;17(4):307-19.
- Zada G, Cavallo LM, Esposito F, et al. Transsphenoidal Surgery in Patients With Acromegaly: Operative Strategies for Overcoming Technically Challenging Anatomical Variations. Neurosurg Focus. 2010 Oct;29(4):E8